



Sección Departamental de Anatomía y Embriología
Facultad de Veterinaria UCM

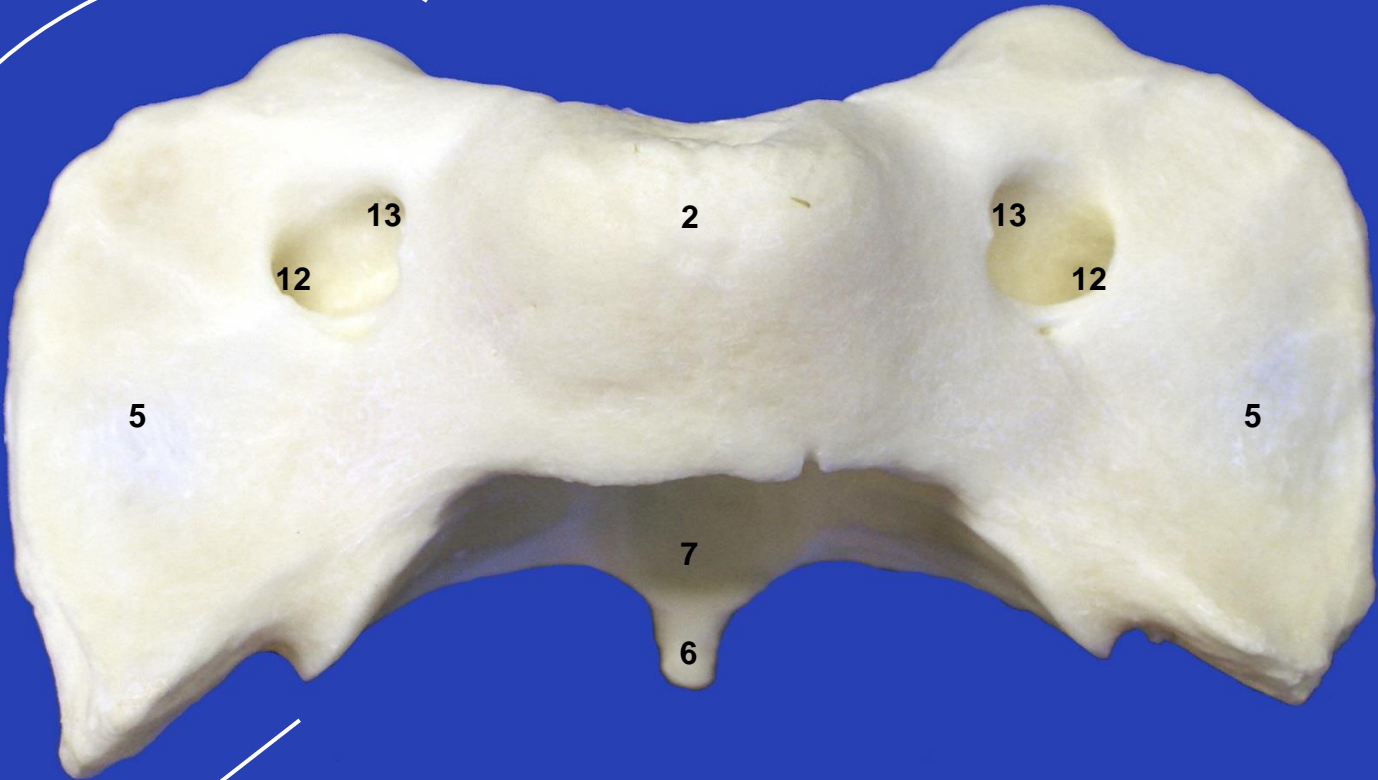
ESQUELETO AXIAL SUIDO



Este obra está bajo una licencia de Creative Commons Reconocimiento-NoComercial-SinObraDerivada 4.0 Internacional.



8



Atlas. Vista dorsal



8

1

1

11

12

12

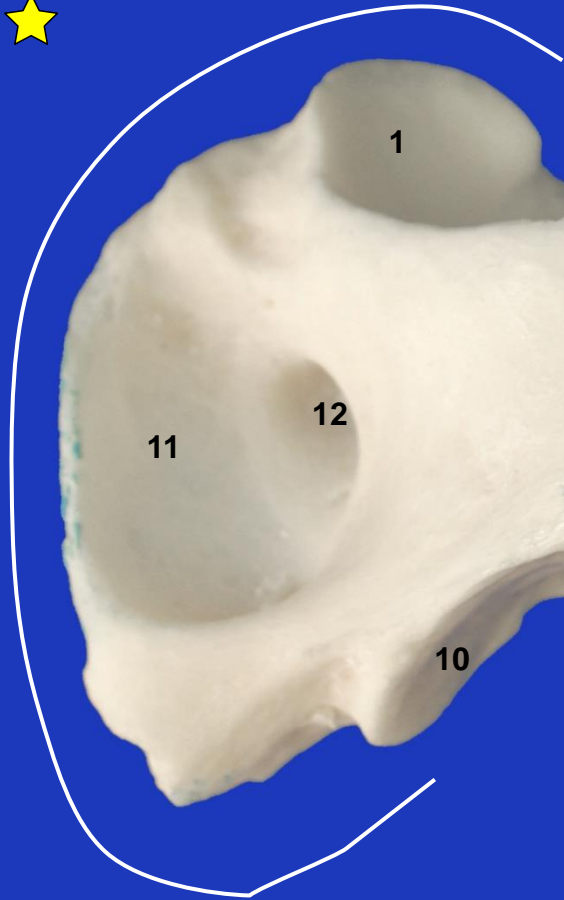
11

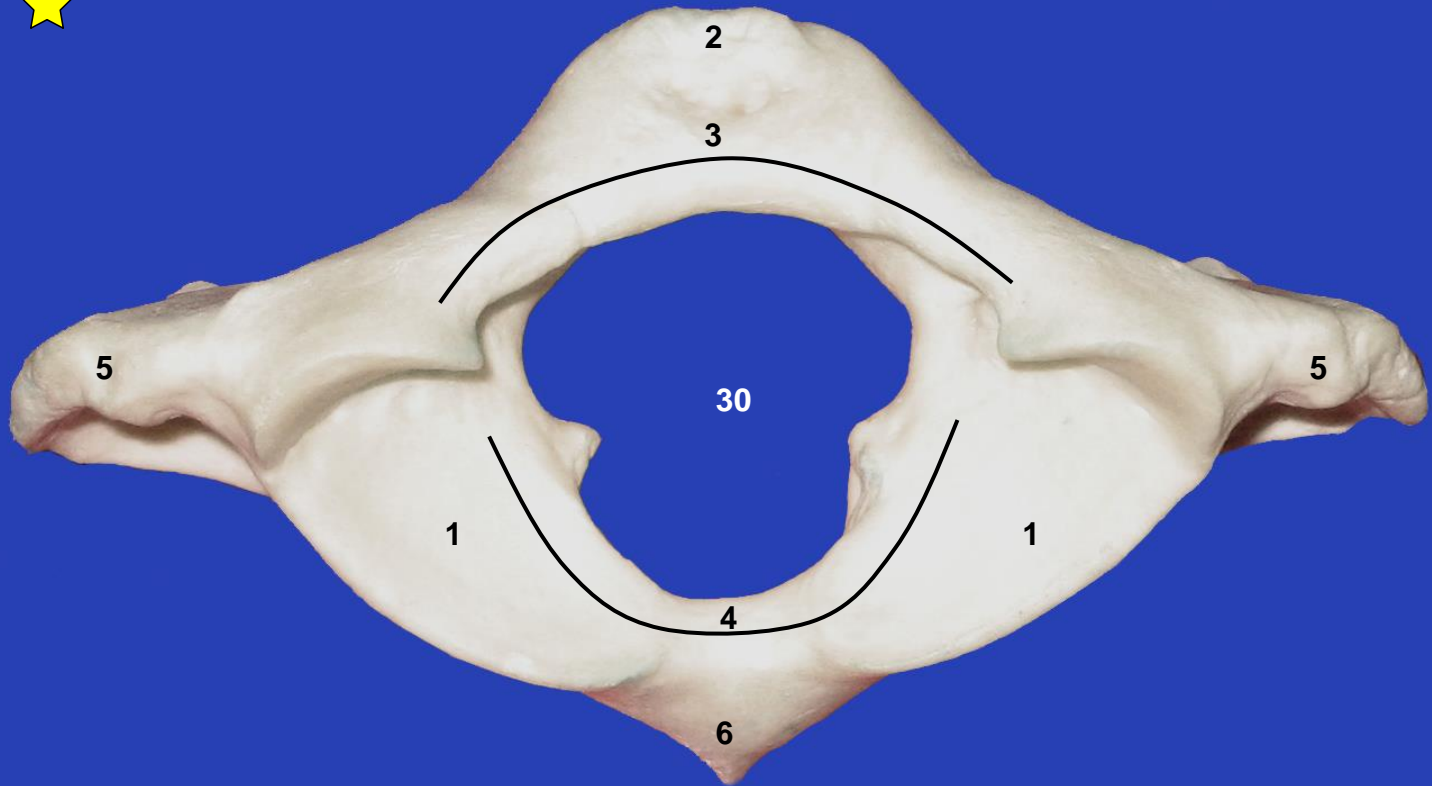
6

10

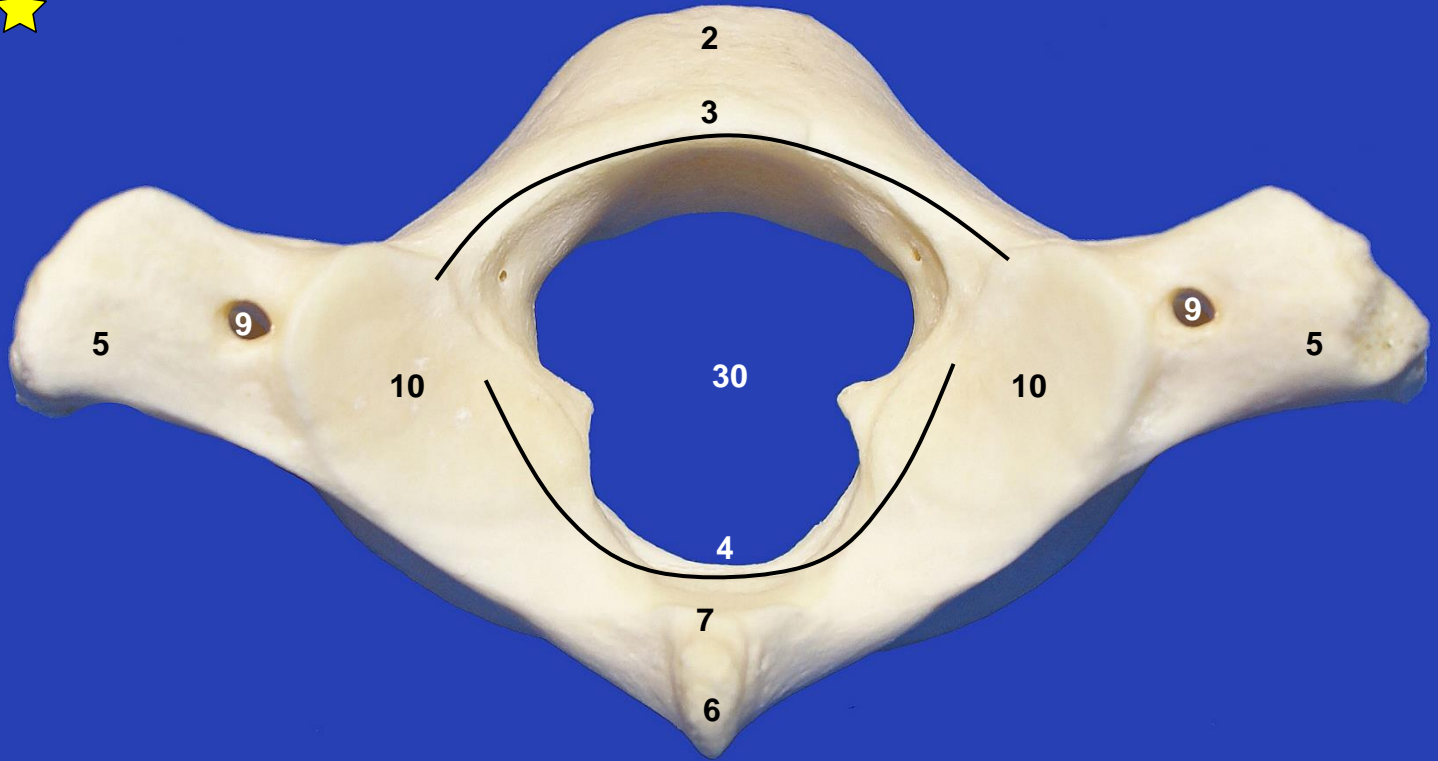
10

Atlas. Vista ventral

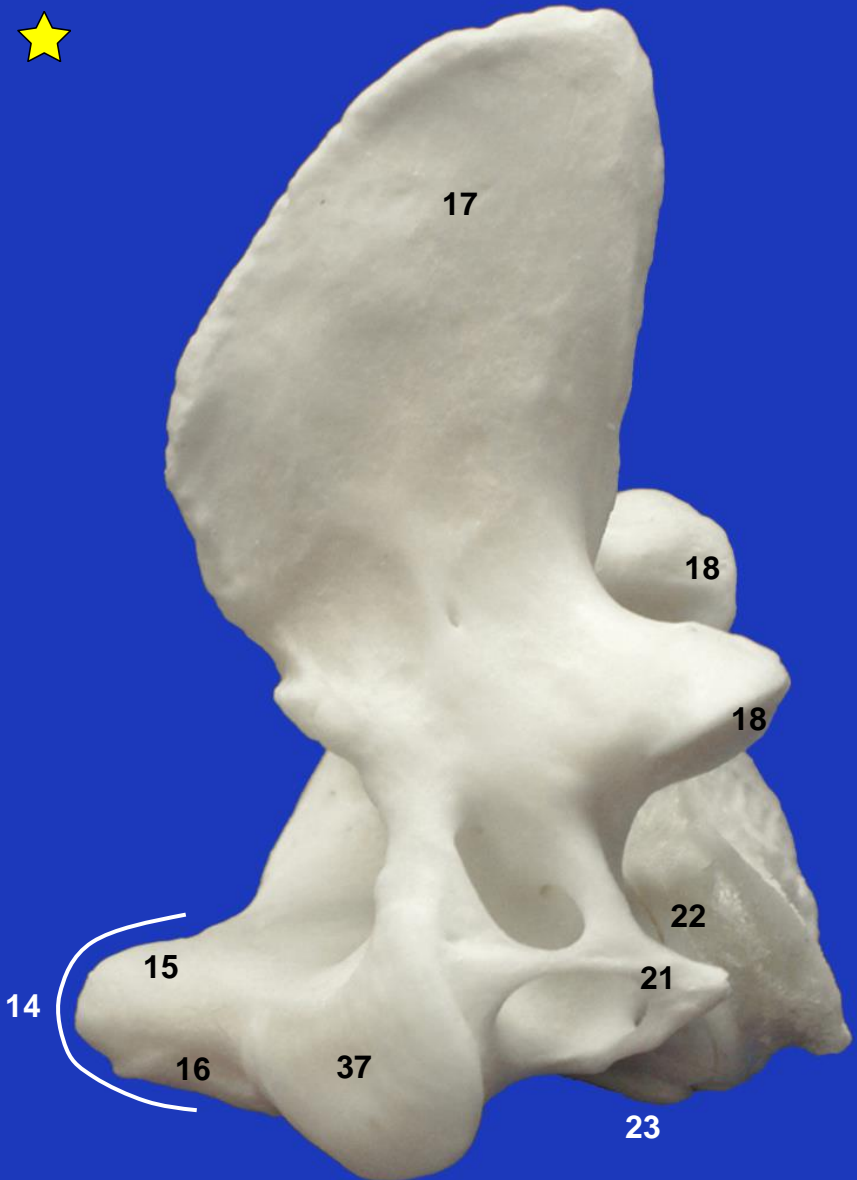




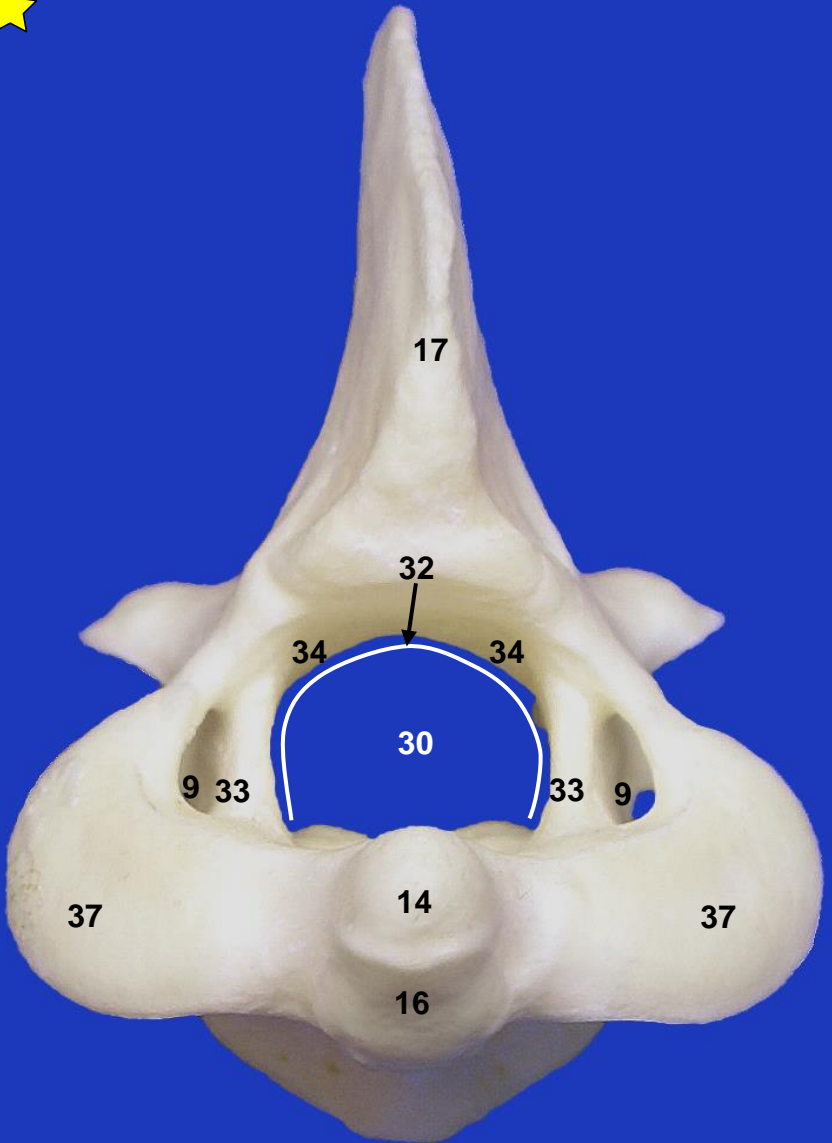
Atlas. Vista craneal



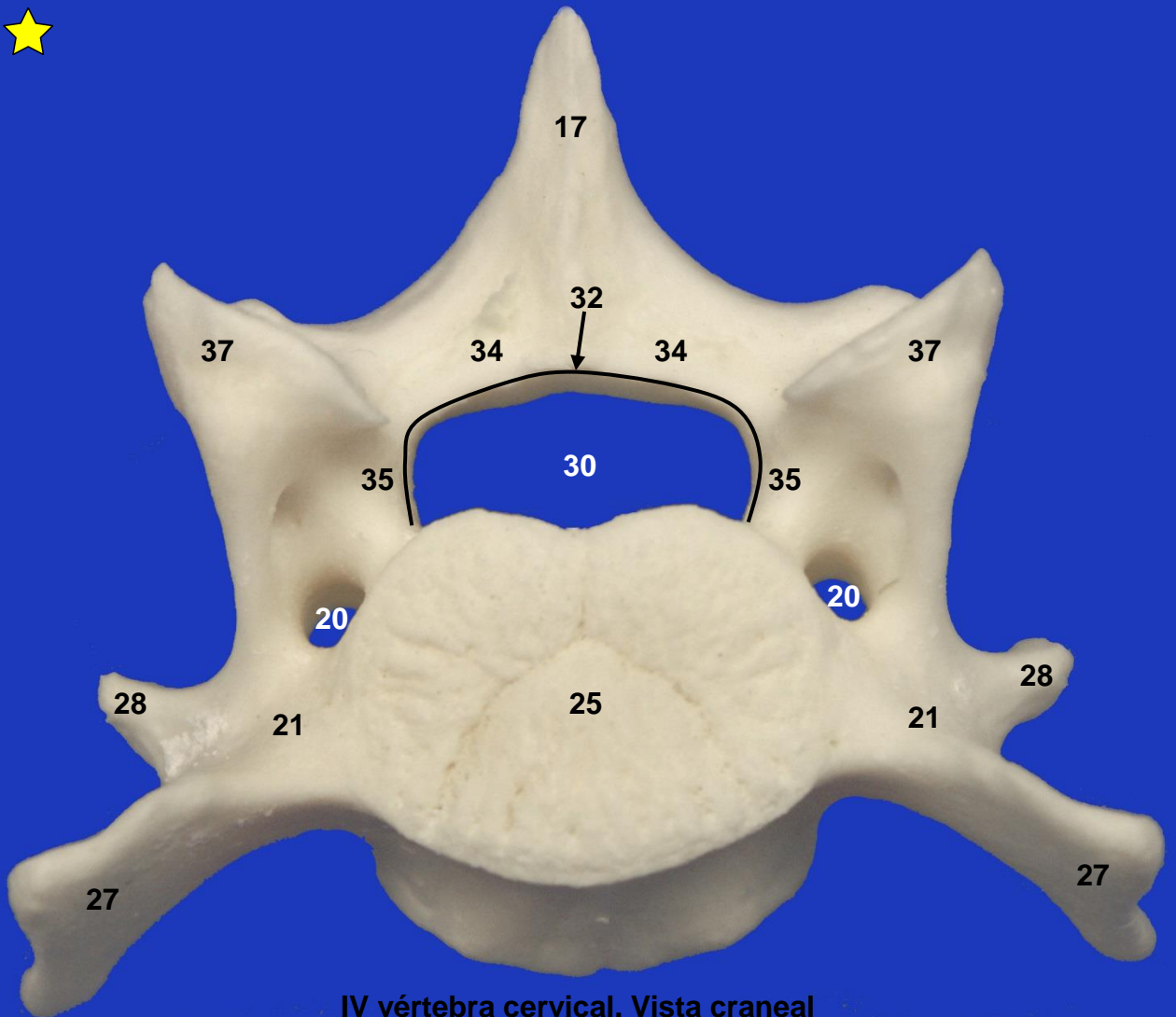
Atlas. Vista caudal



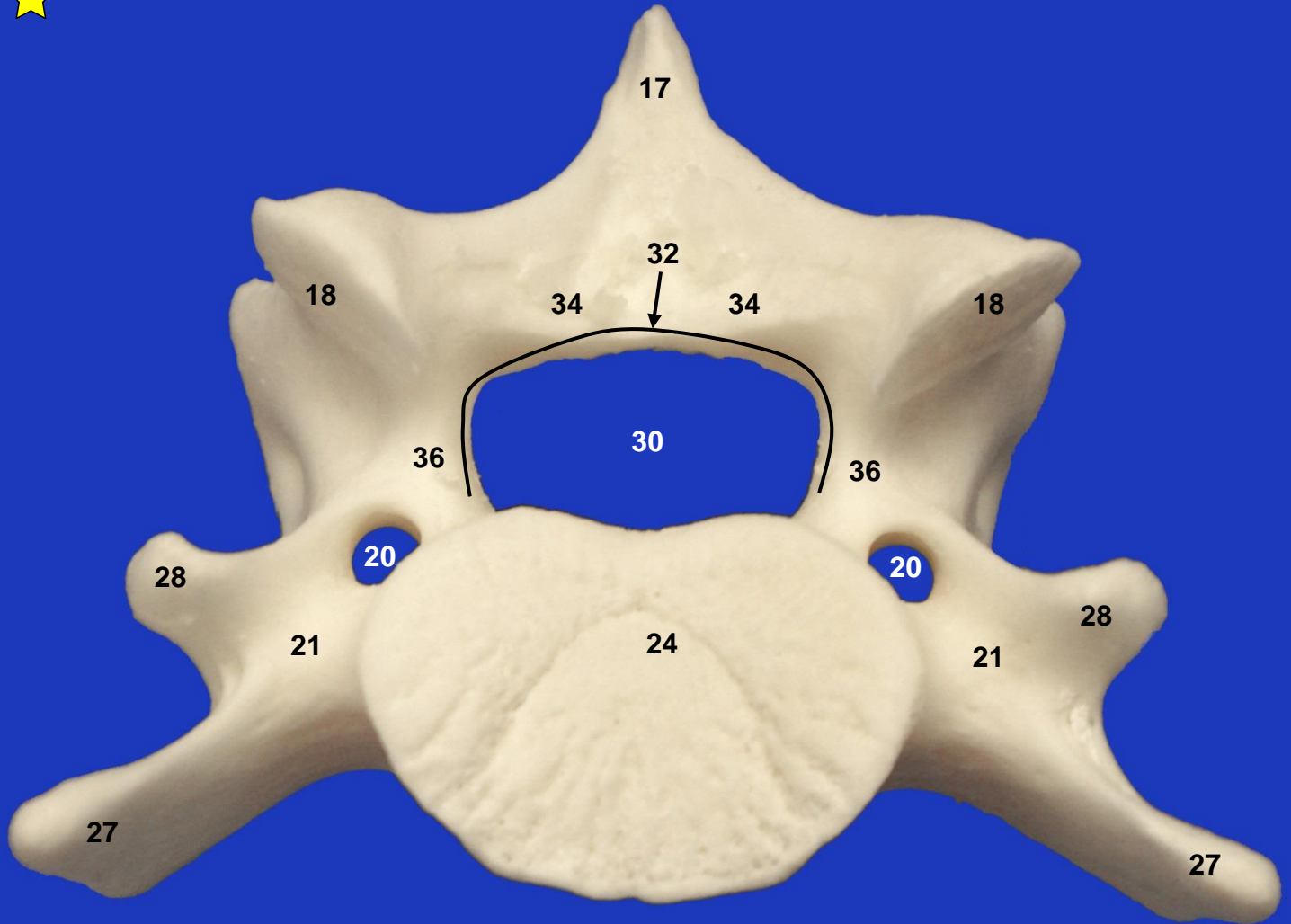
Axis. Vista lateral izquierda



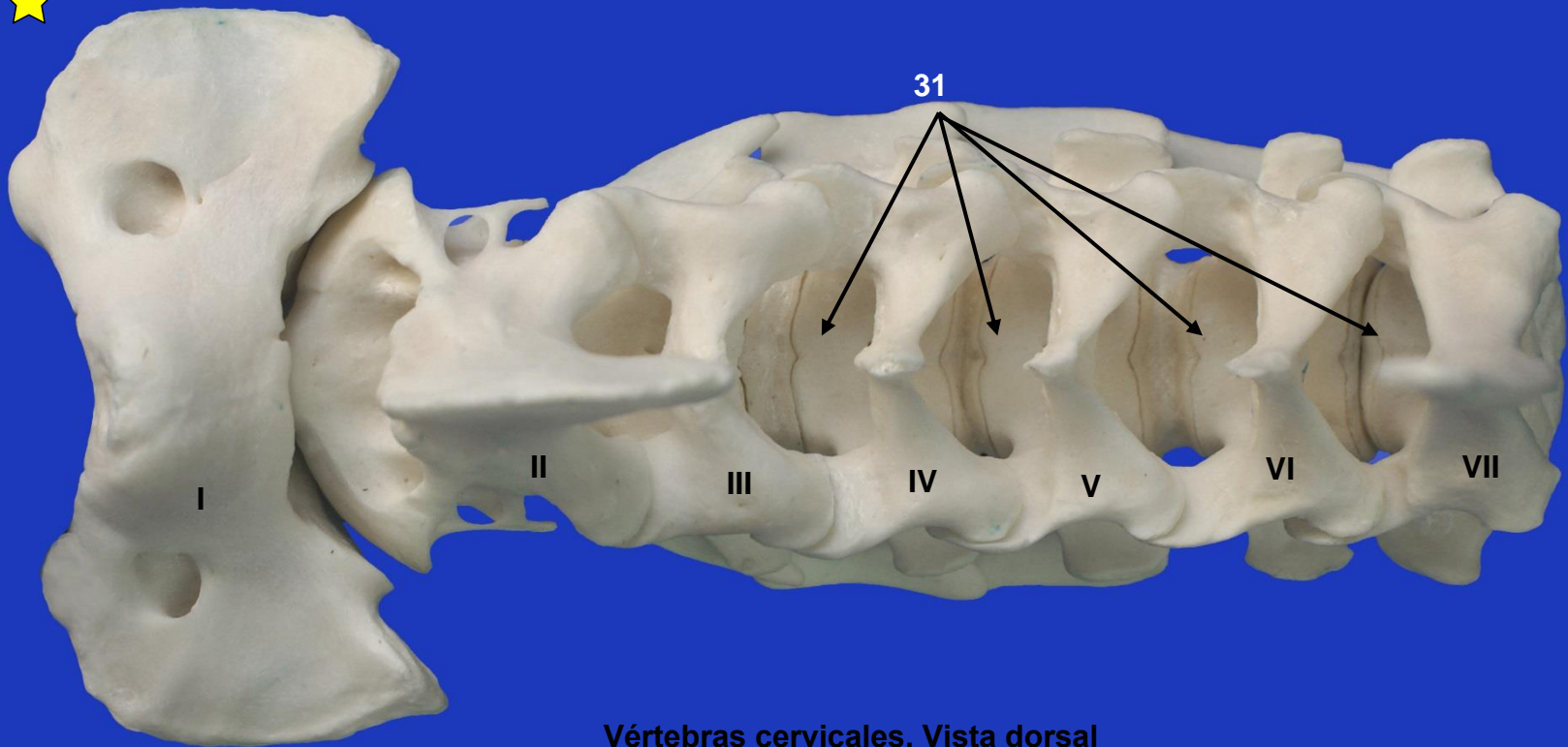
Axis. Vista craneal



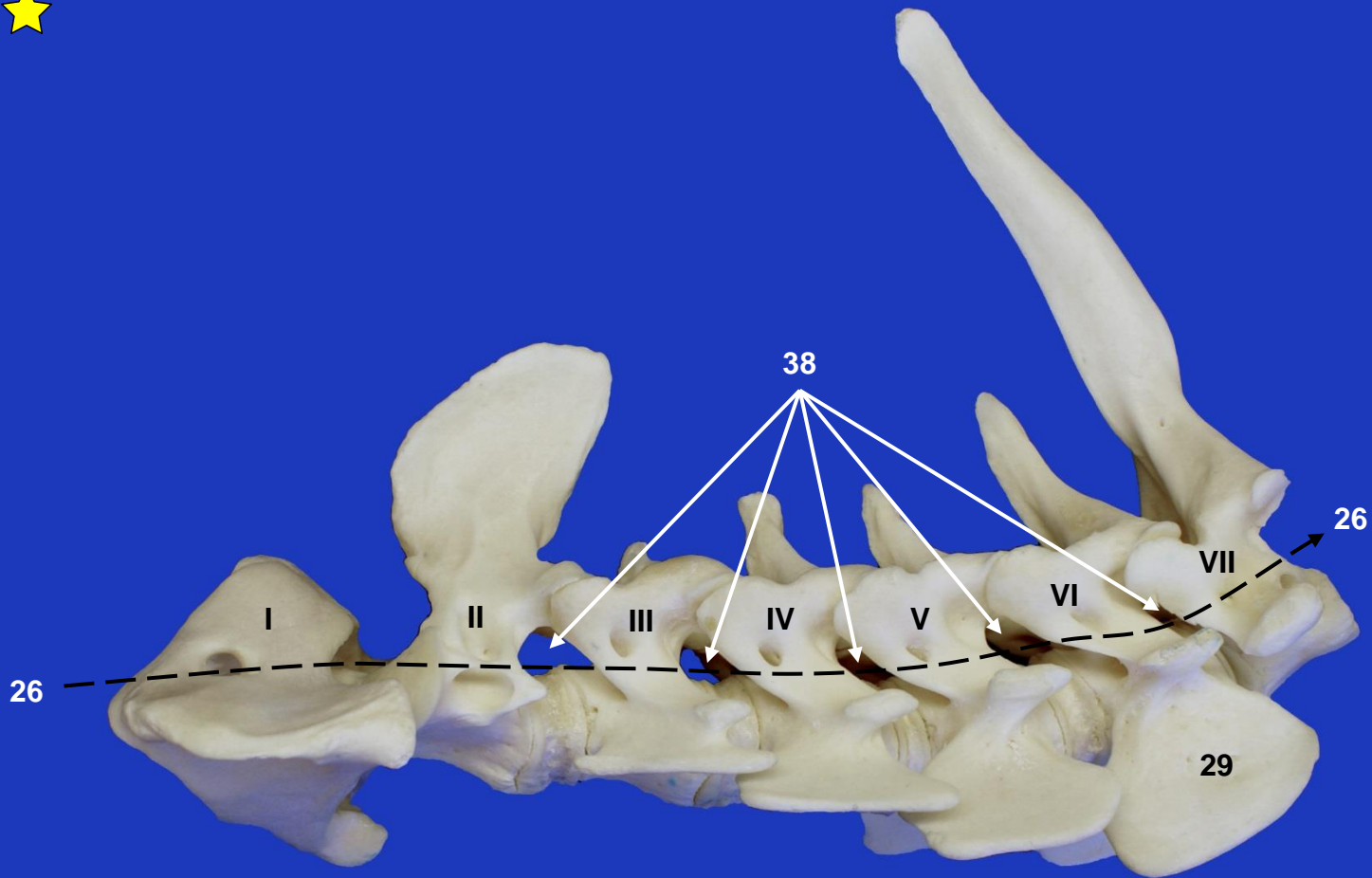
IV vértebra cervical. Vista craneal



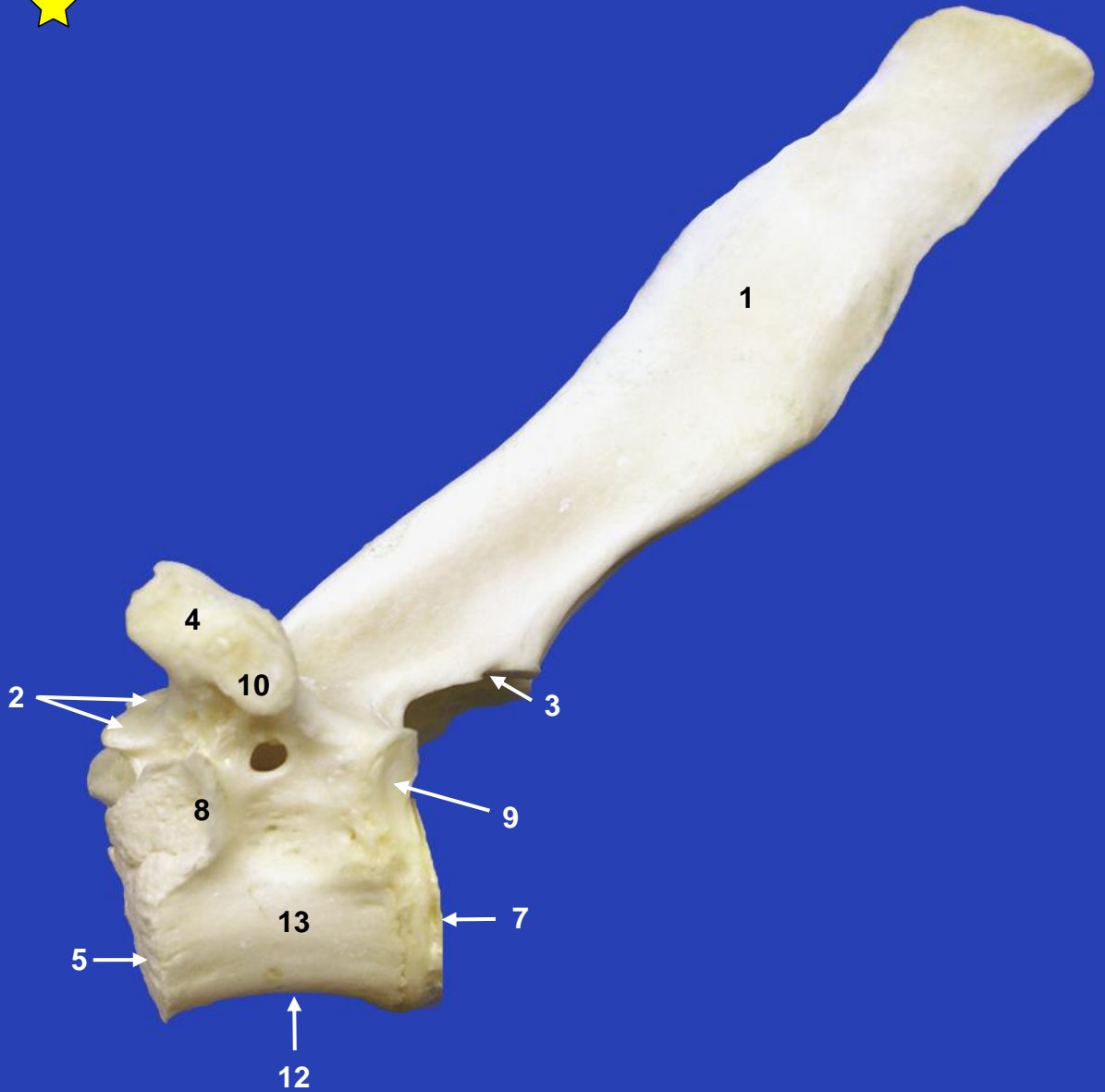
IV vértebra cervical. Vista caudal



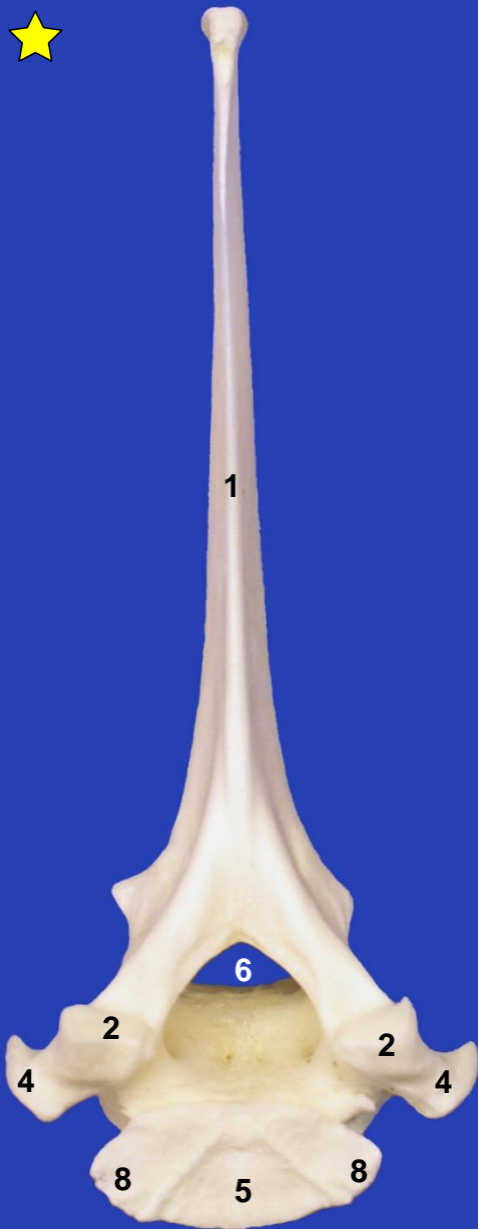
Vértebras cervicales. Vista dorsal



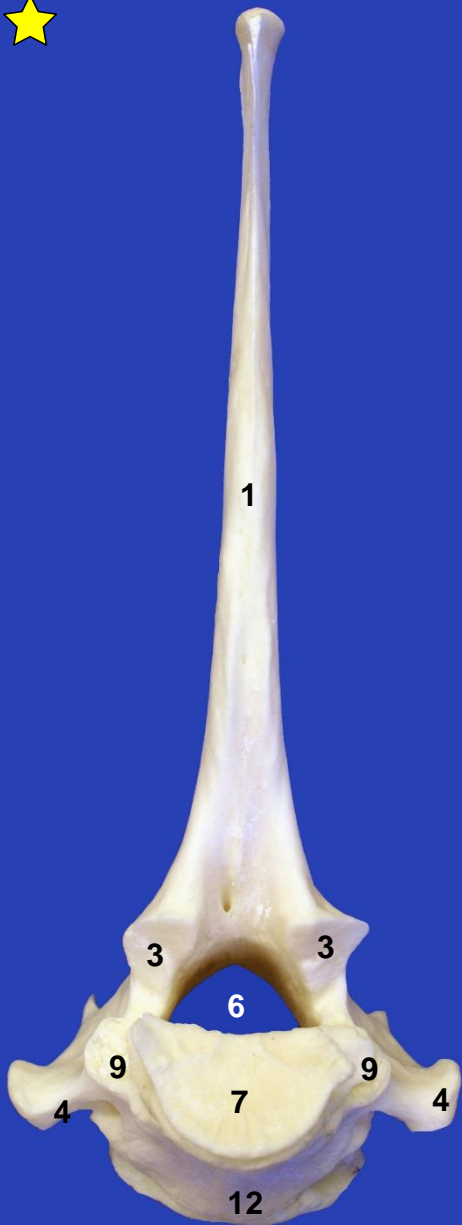Vértebras cervicales. Vista lateral izquierda



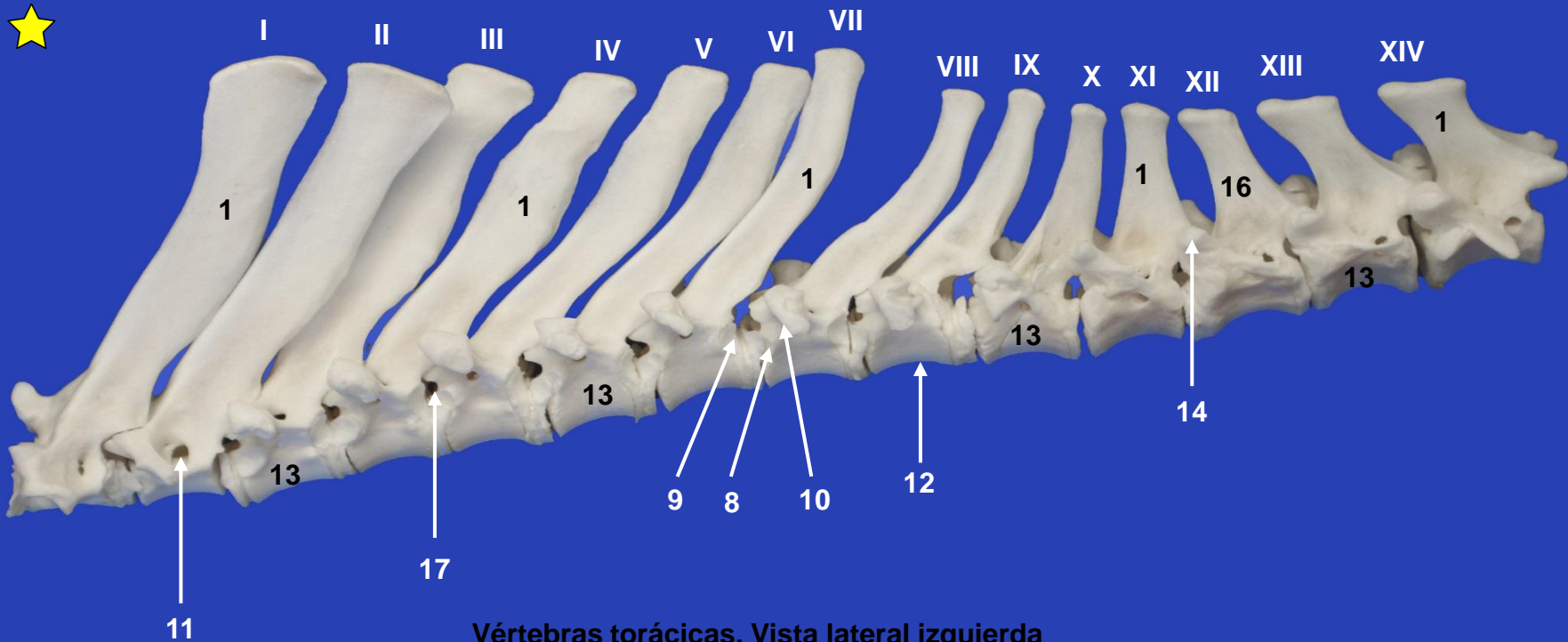
Vértebra torácica. Vista lateral izquierda



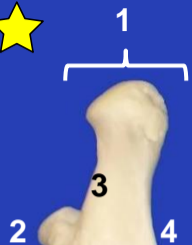Vértebra torácica. Vista craneal



Vértebra torácica. Vista caudal



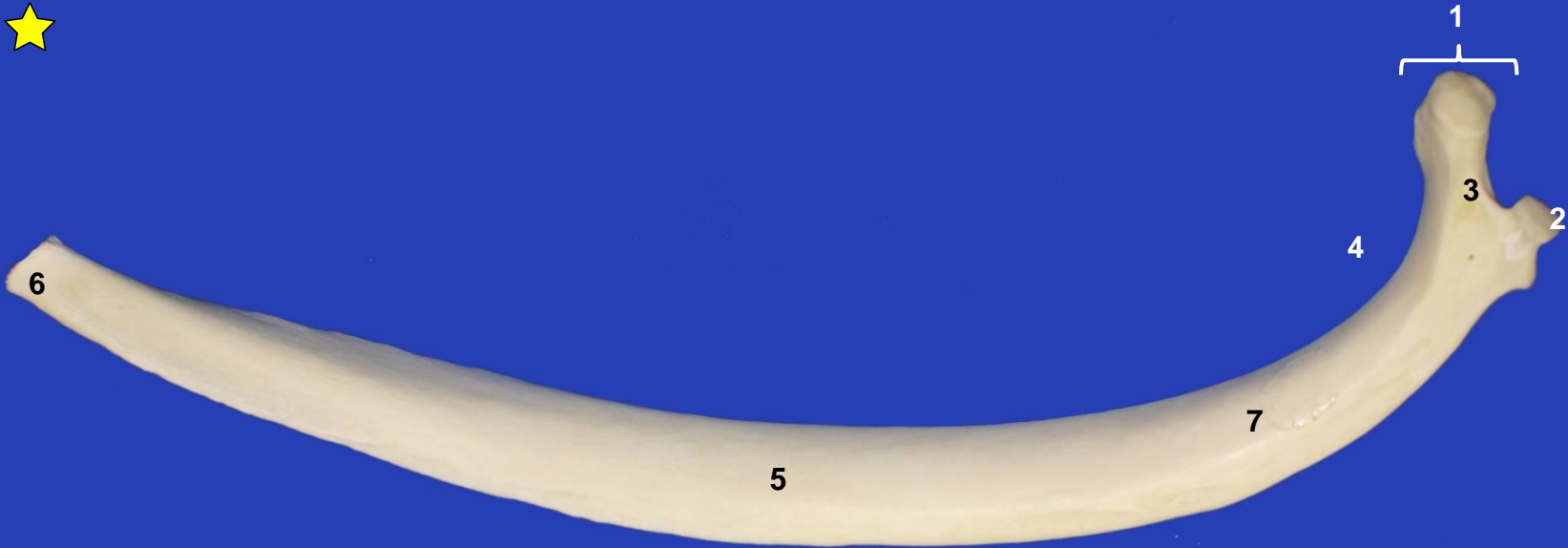Vértebras torácicas. Vista lateral izquierda



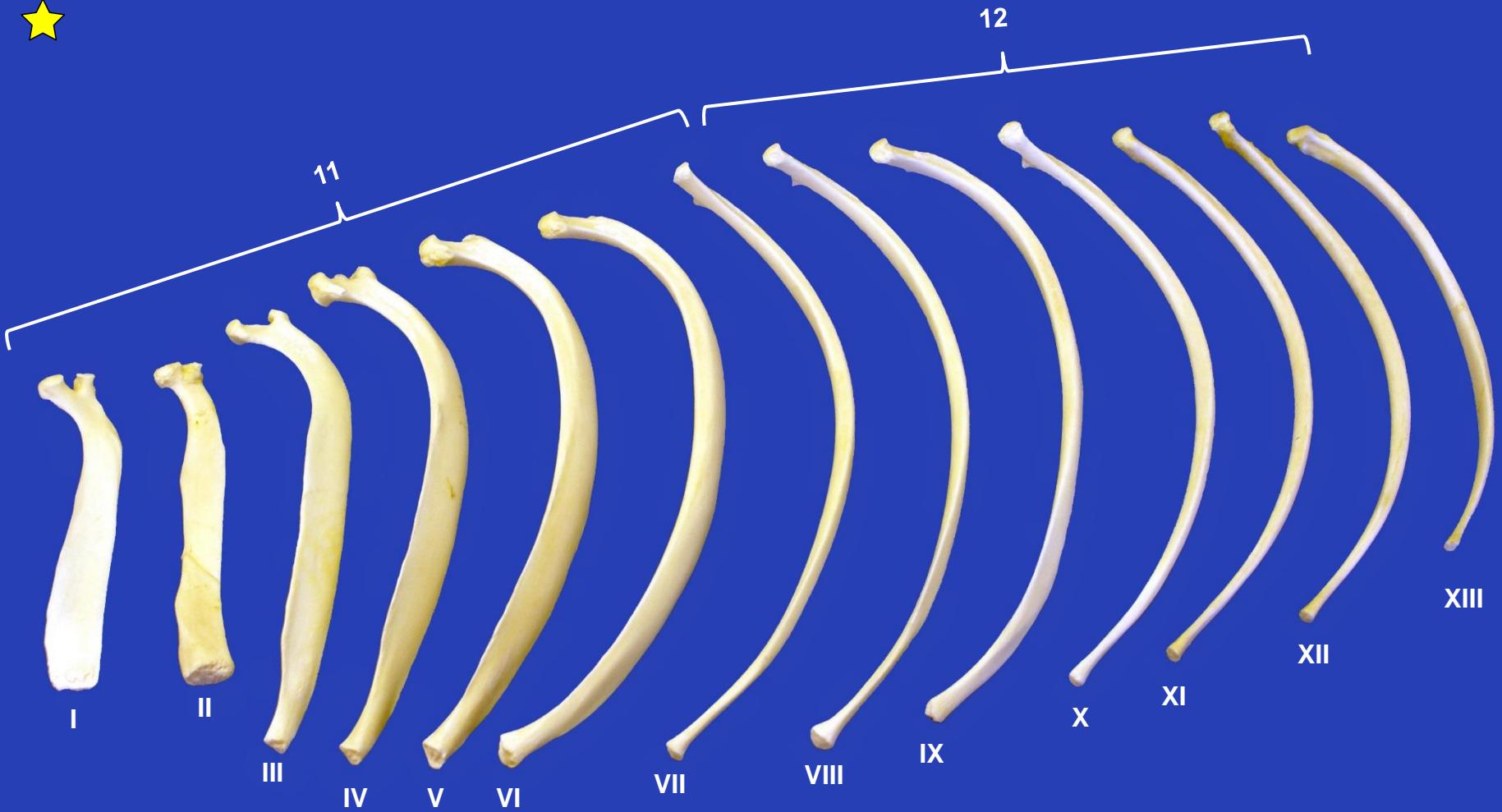
5

6

Costilla. Vista lateral



Costilla. Vista medial



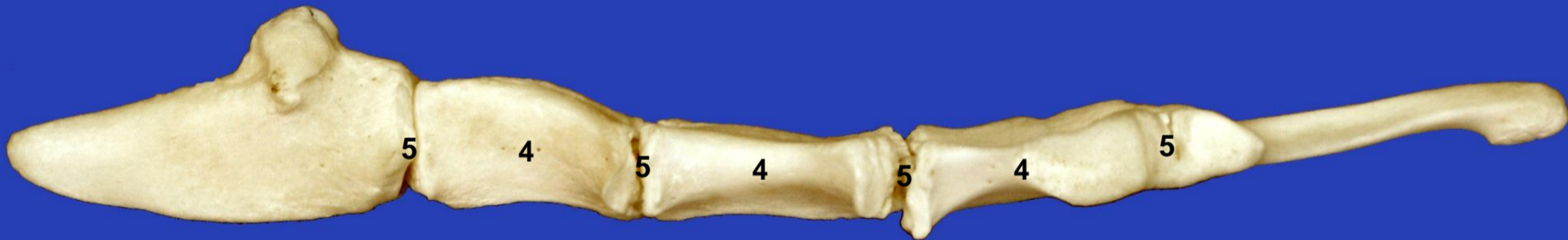
Secuencia de costillas. Vista lateral izquierda



1

2

3



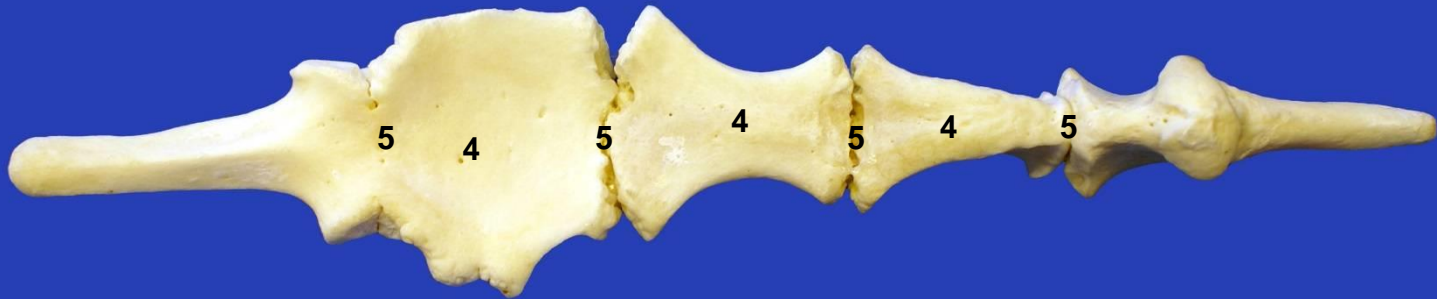
Esternón. Vista lateral izquierda



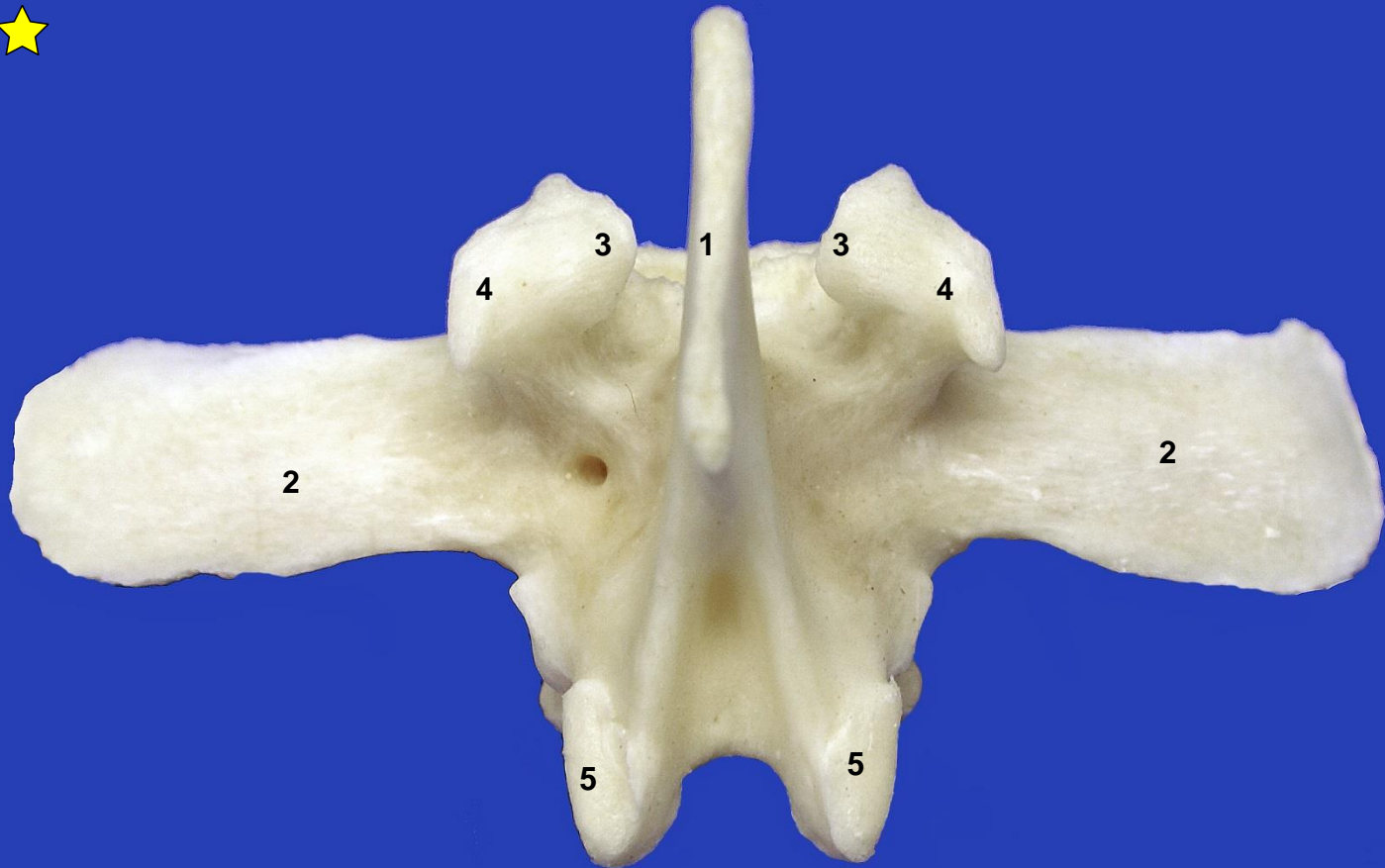
1

2

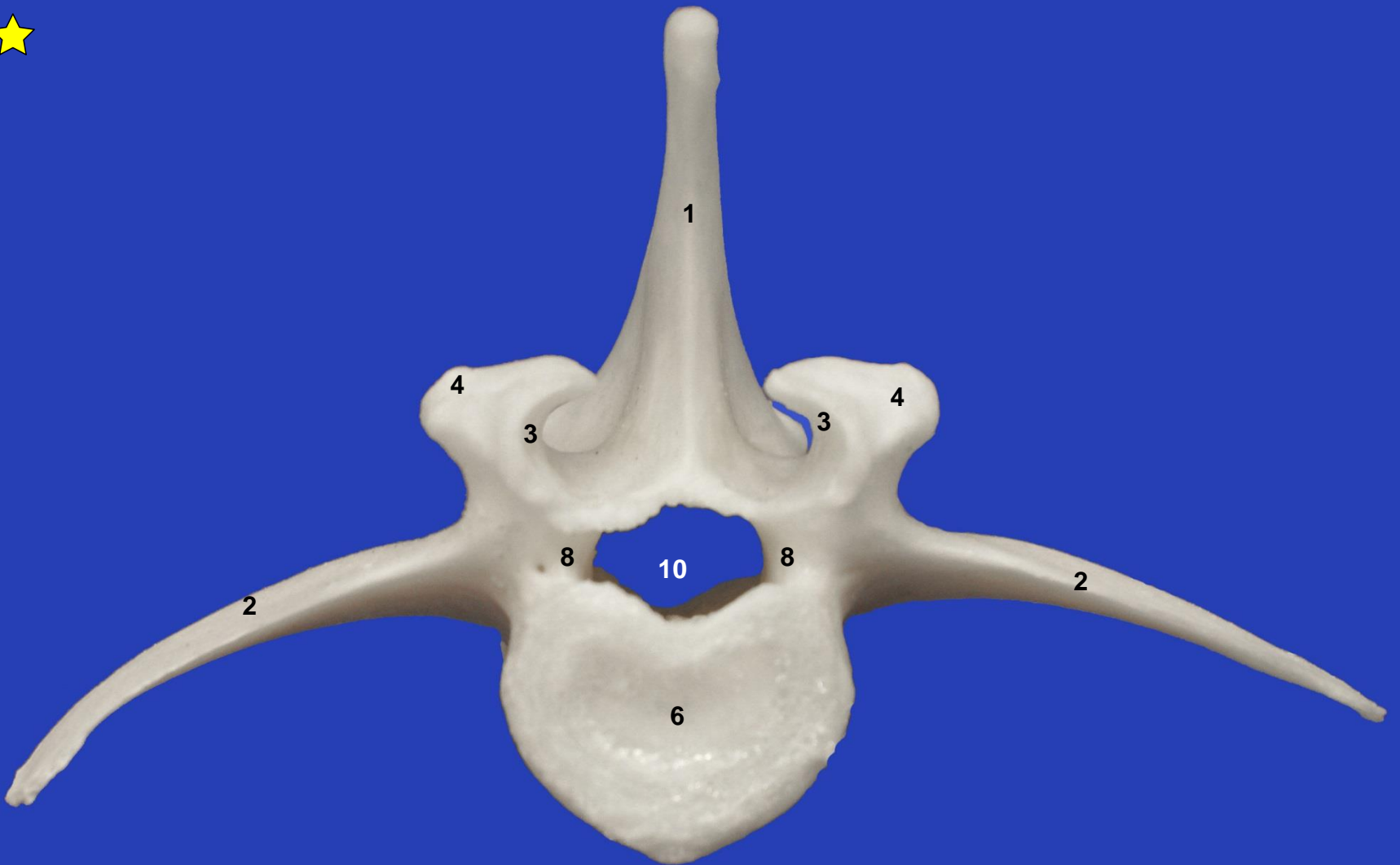
3



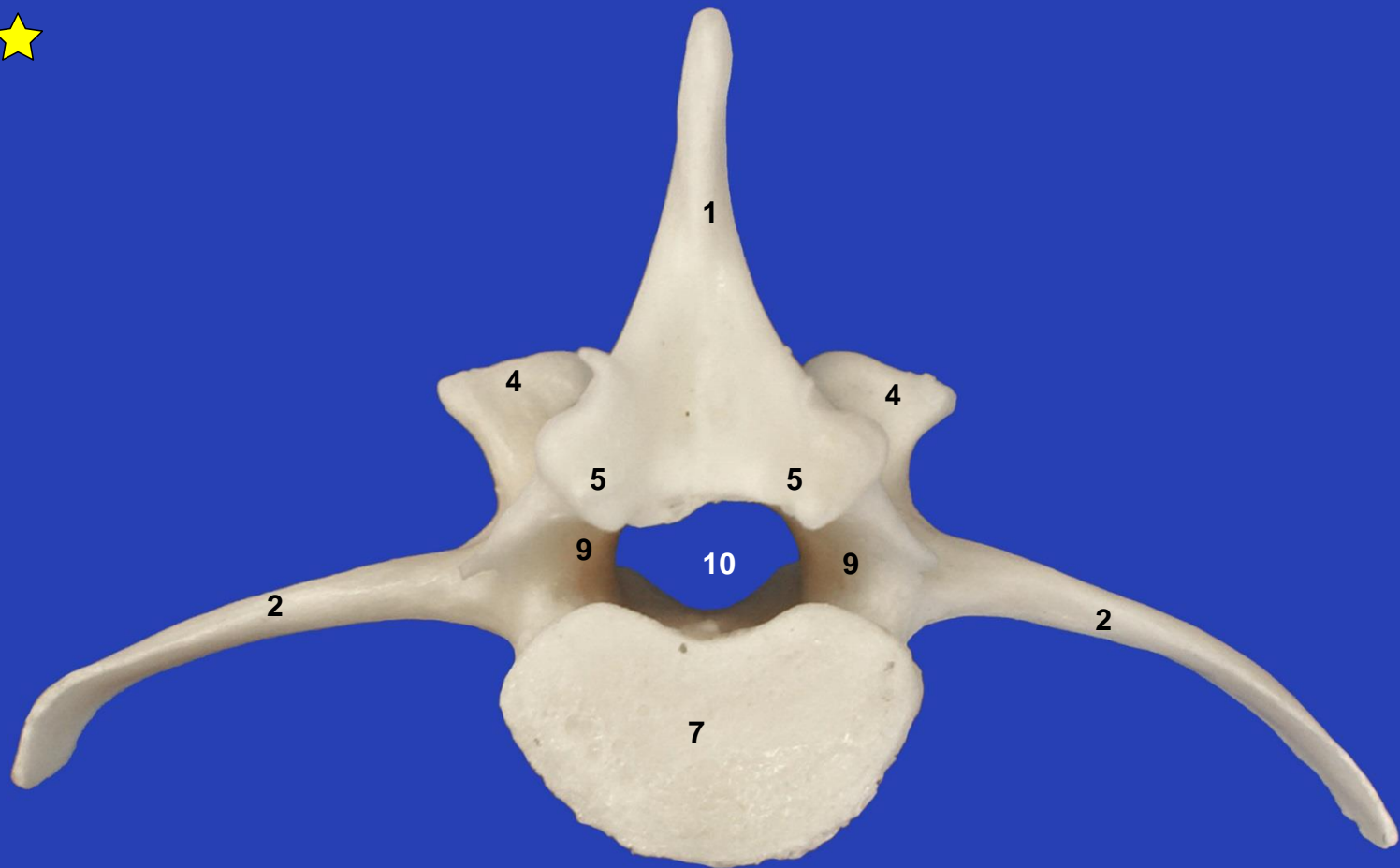
Esternón. Vista dorsal



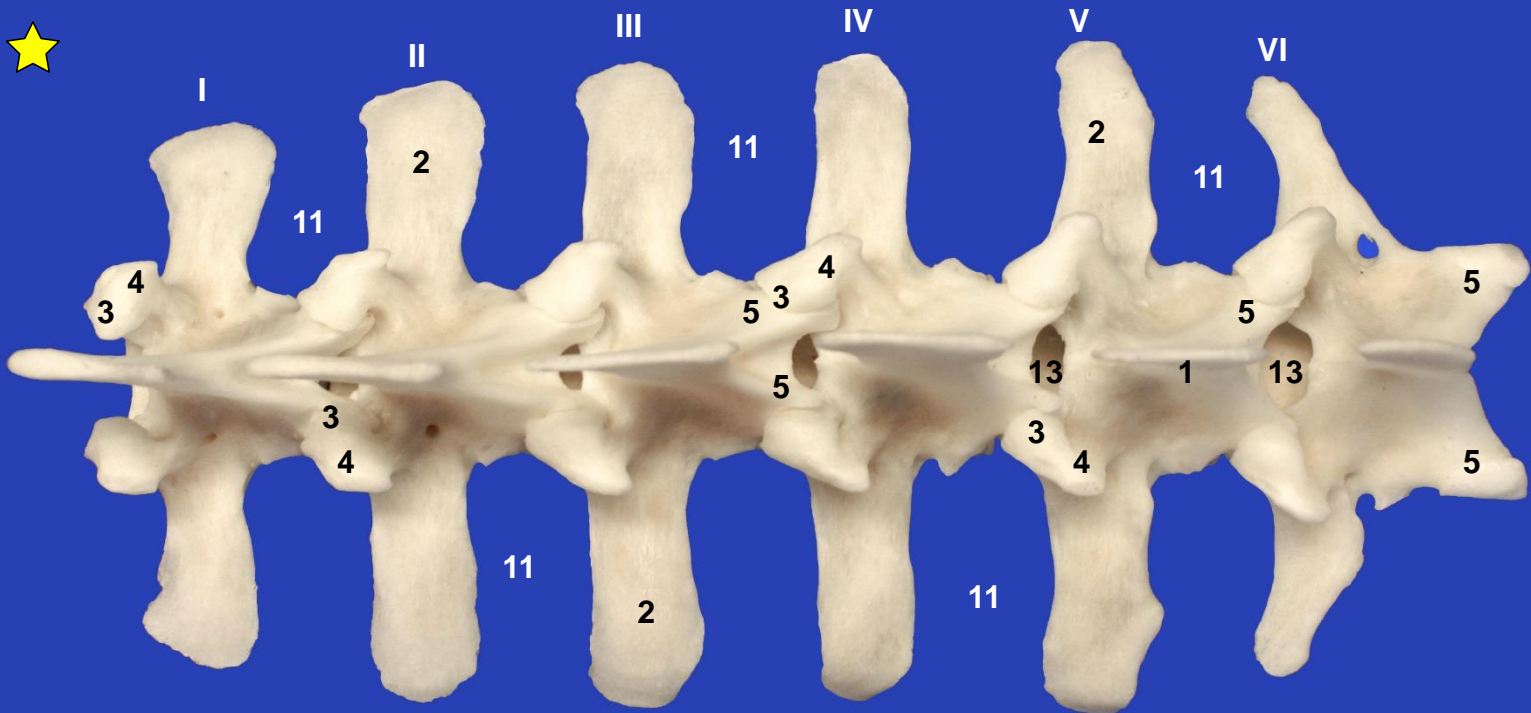
Vértebra lumbar. Vista dorsal



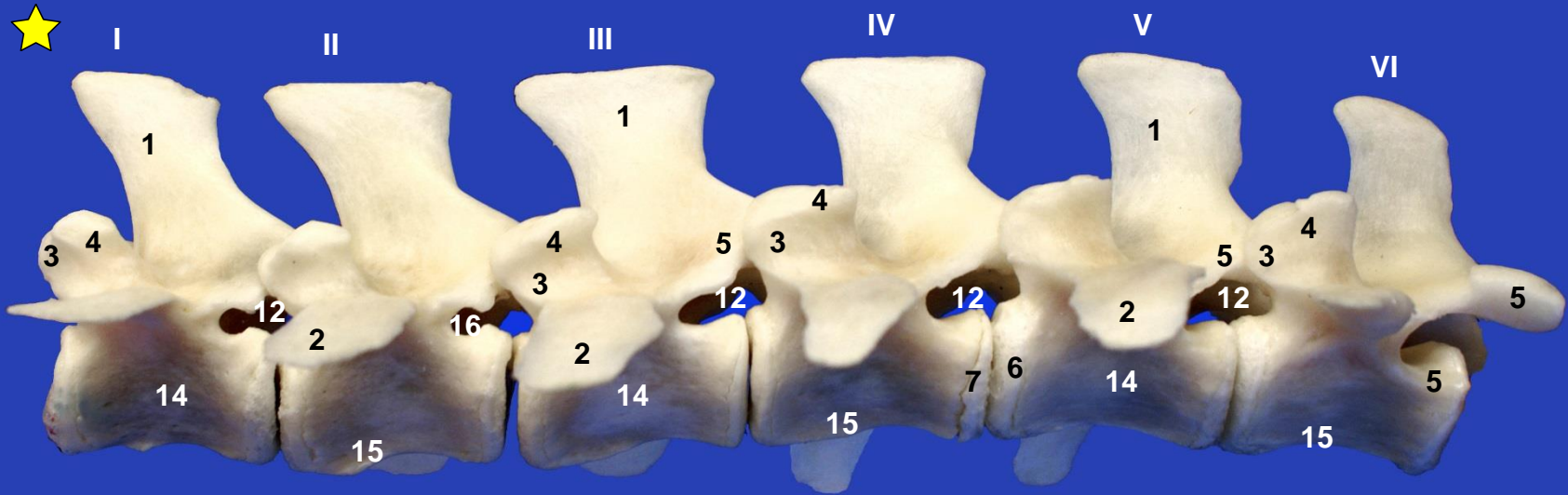
Vértebra lumbar. Vista craneal



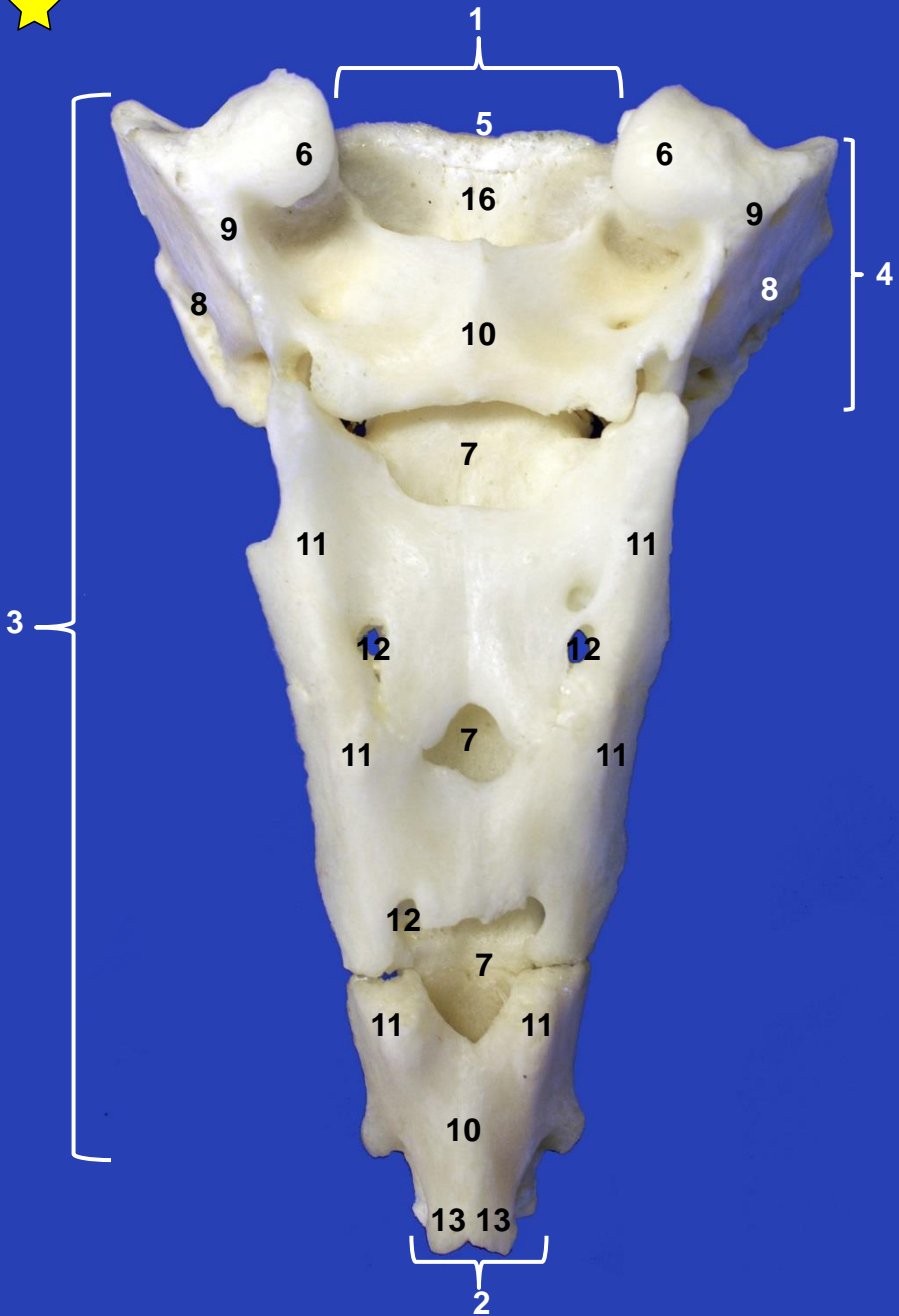
Vértebra lumbar. Vista caudal



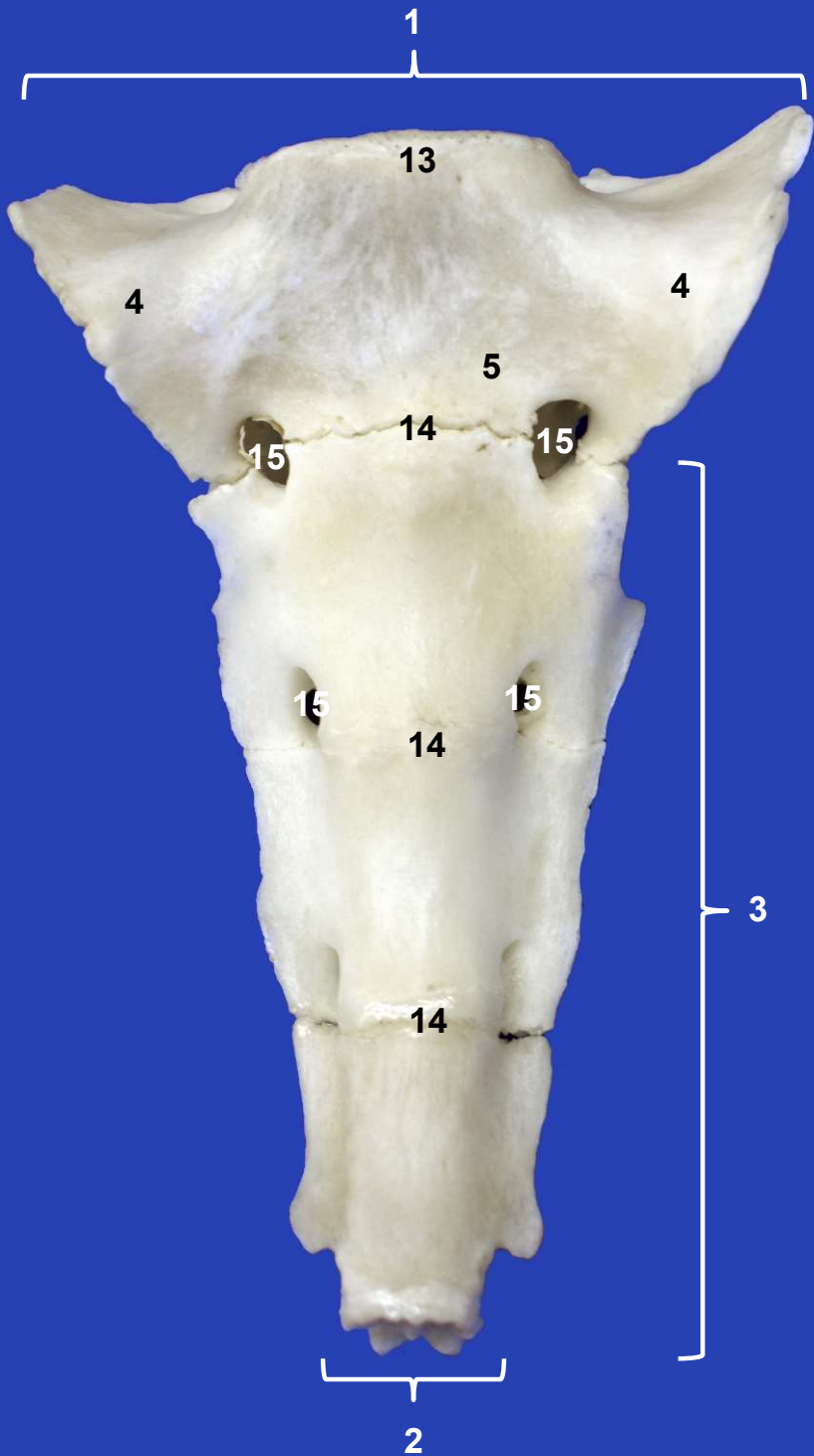
Vértebras lumbares. Vista dorsal



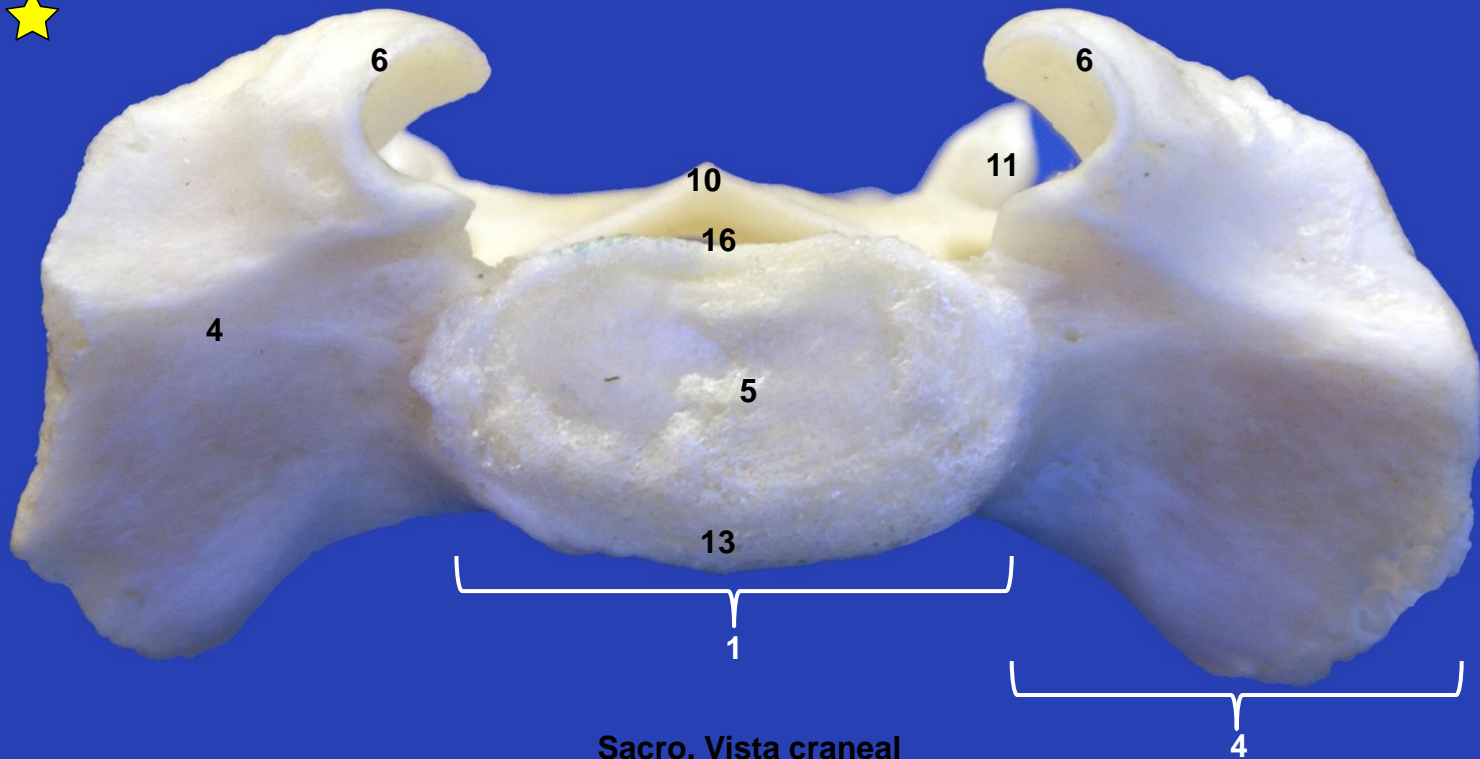
Vértebras lumbares. Vista lateral izquierda

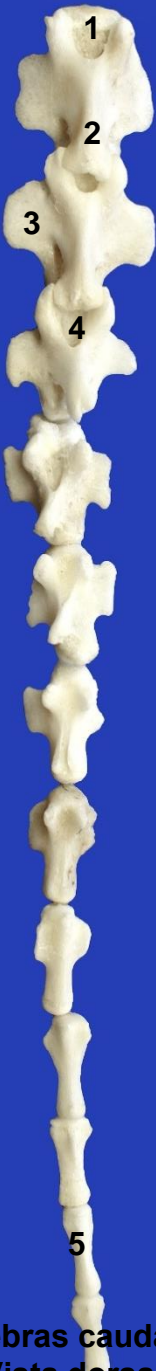

Sacro. Vista dorsal



Sacro. Vista ventral o pélvica





**Vértebras caudales.
Vista dorsal**