

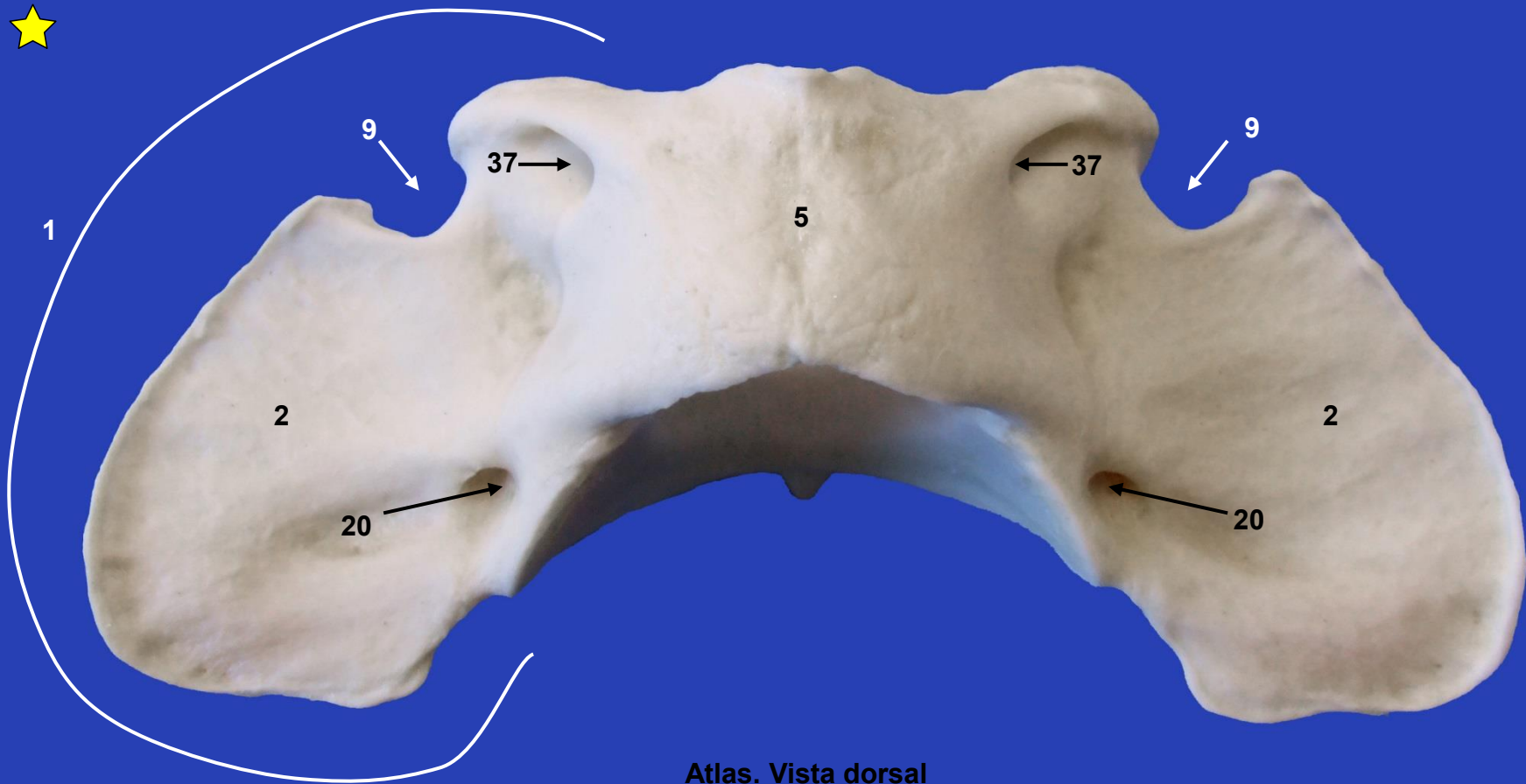


Sección Departamental de Anatomía y Embriología
Facultad de Veterinaria UCM

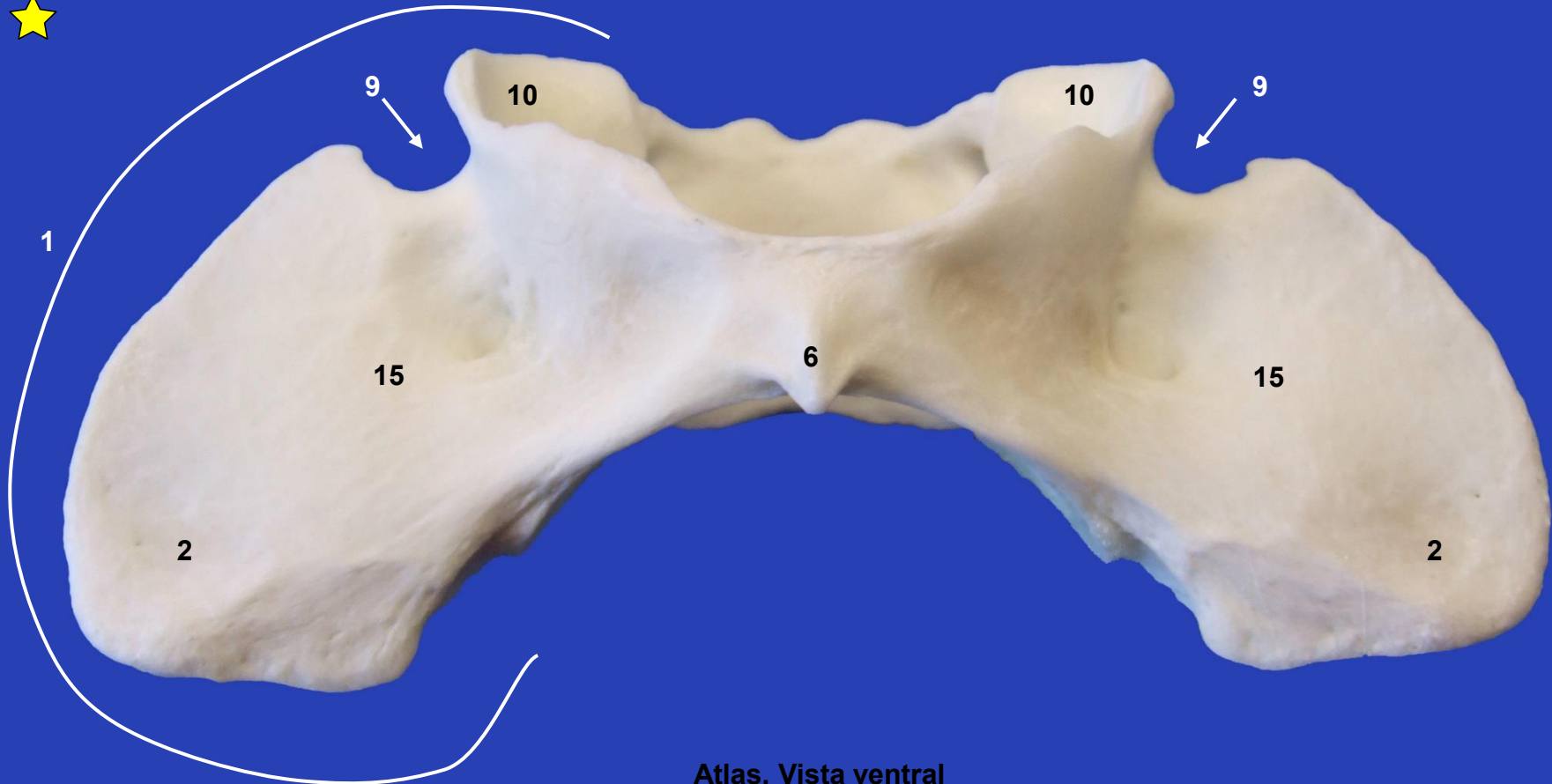
ESQUELETO AXIAL PERRO



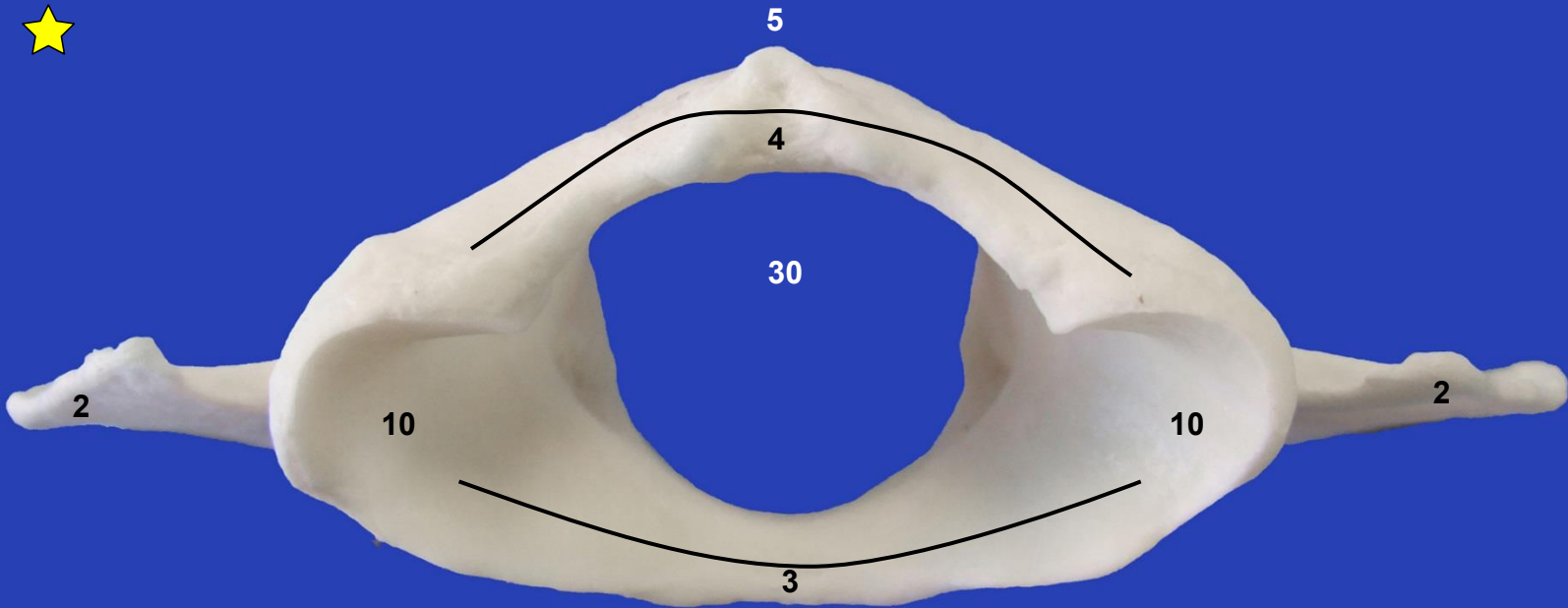
Este obra está bajo una licencia de Creative Commons Reconocimiento-NoComercial-SinObraDerivada 4.0 Internacional.



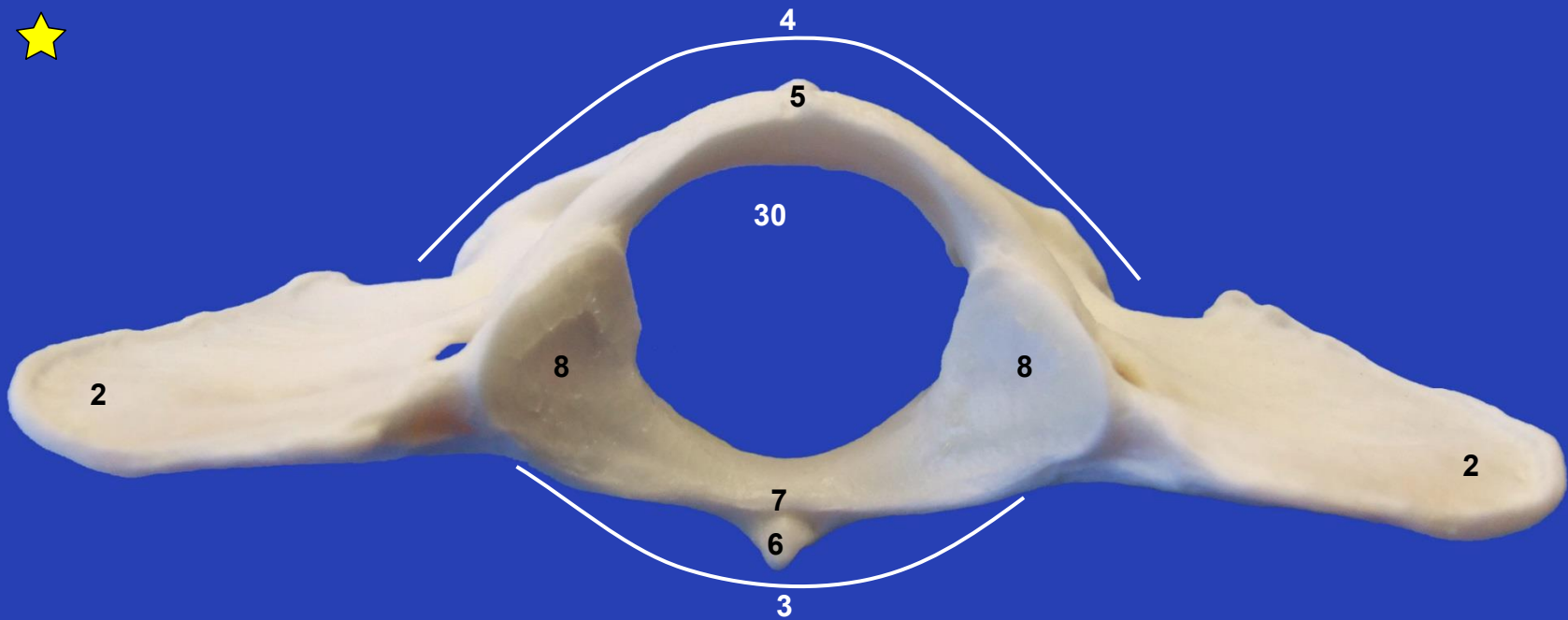
Atlas. Vista dorsal



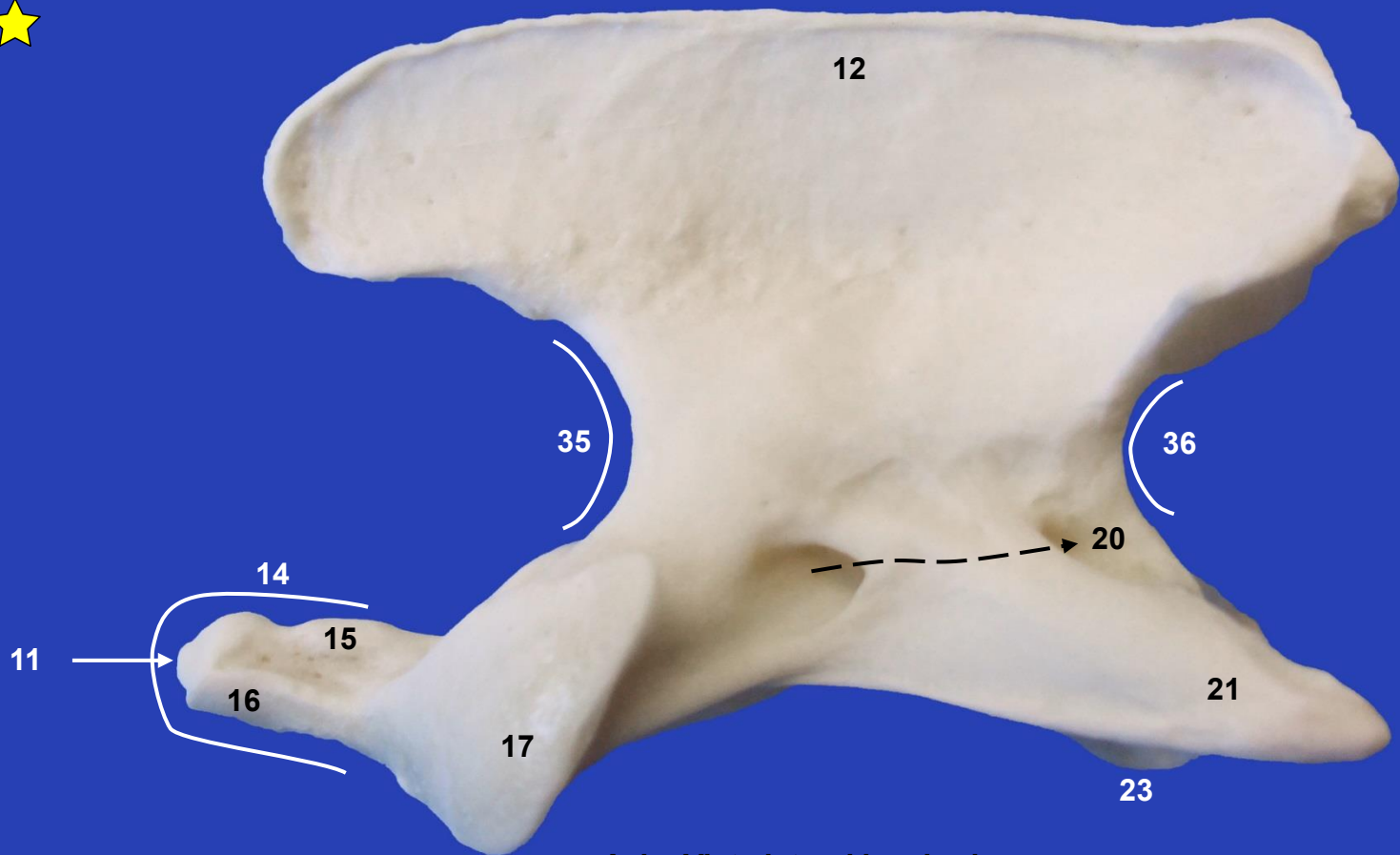
Atlas. Vista ventral



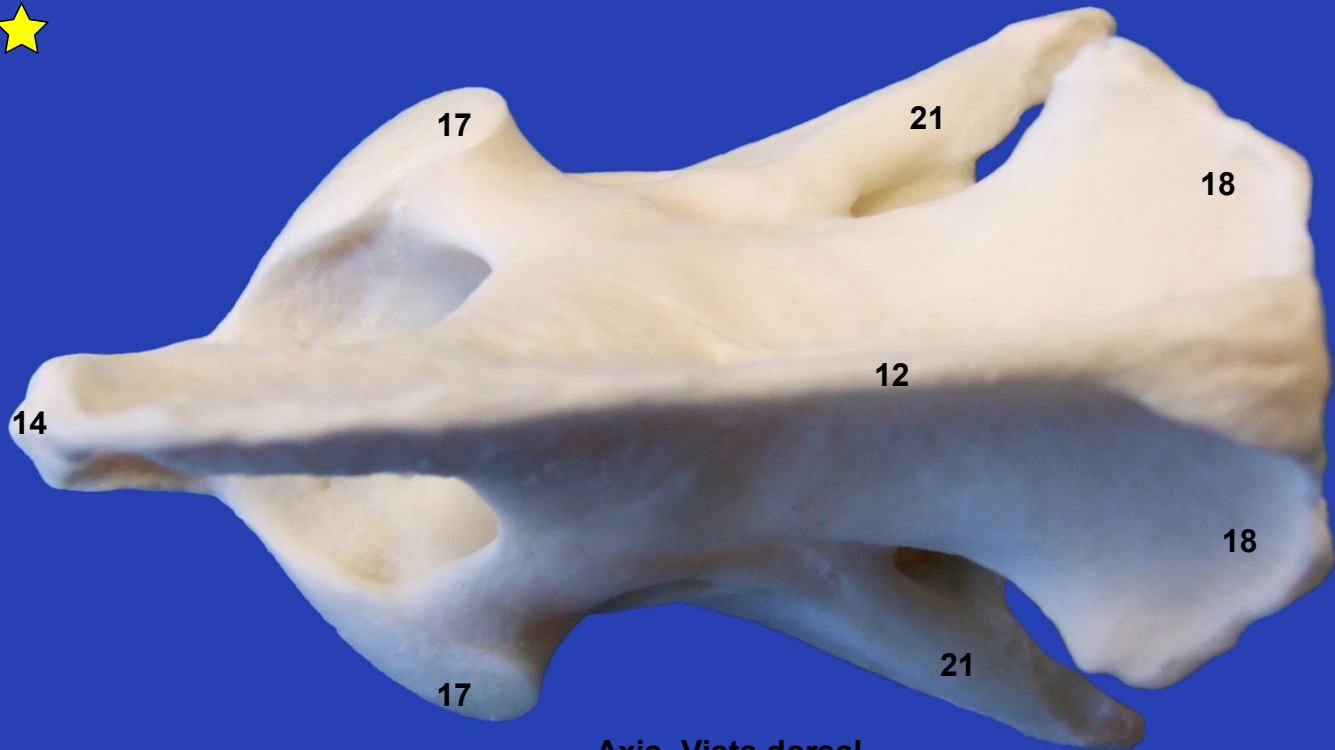Atlas. Vista craneal



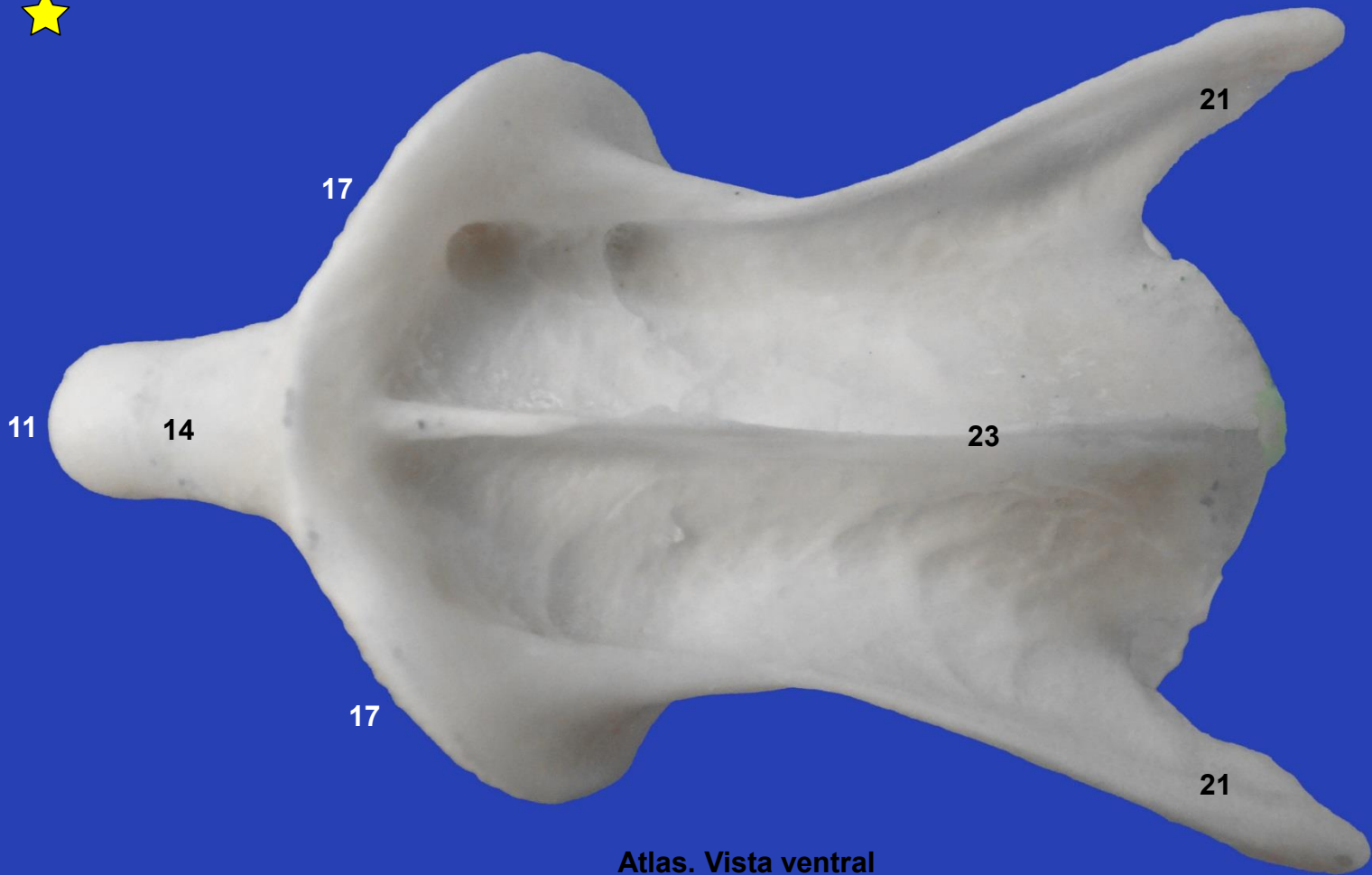
Atlas. Vista caudal



Axis. Vista lateral izquierda



Axis. Vista dorsal



Atlas. Vista ventral



12

30

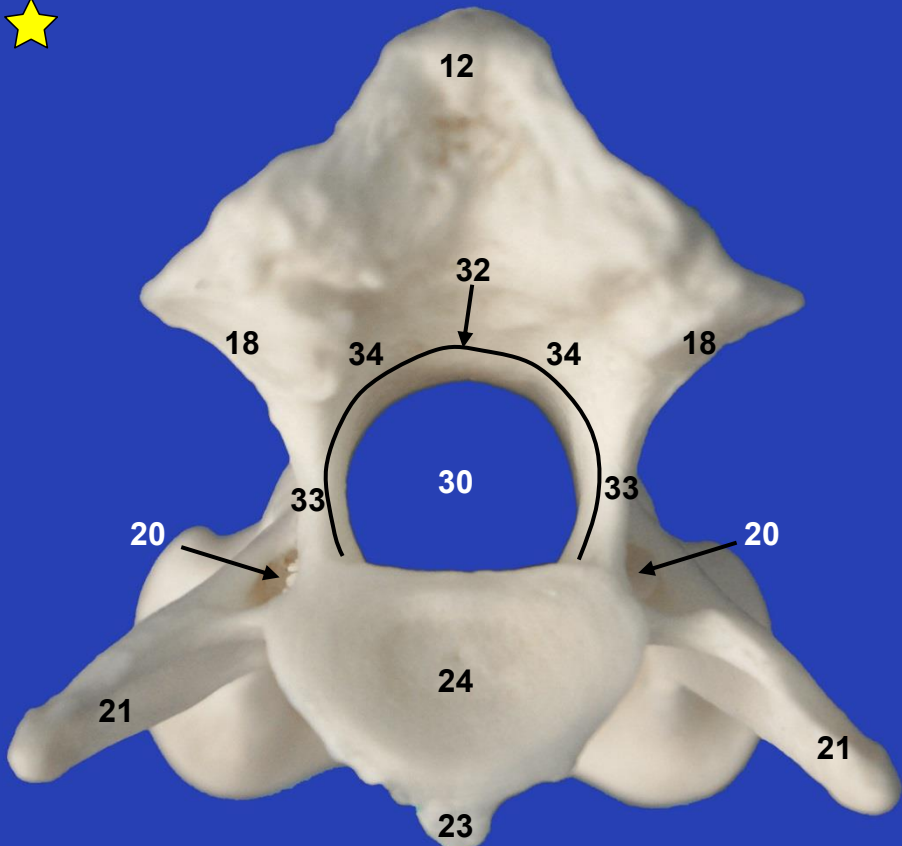
22

14

17

17

Axis. Vista craneal



12

32

18

34

34

18

30

20

33

33

20

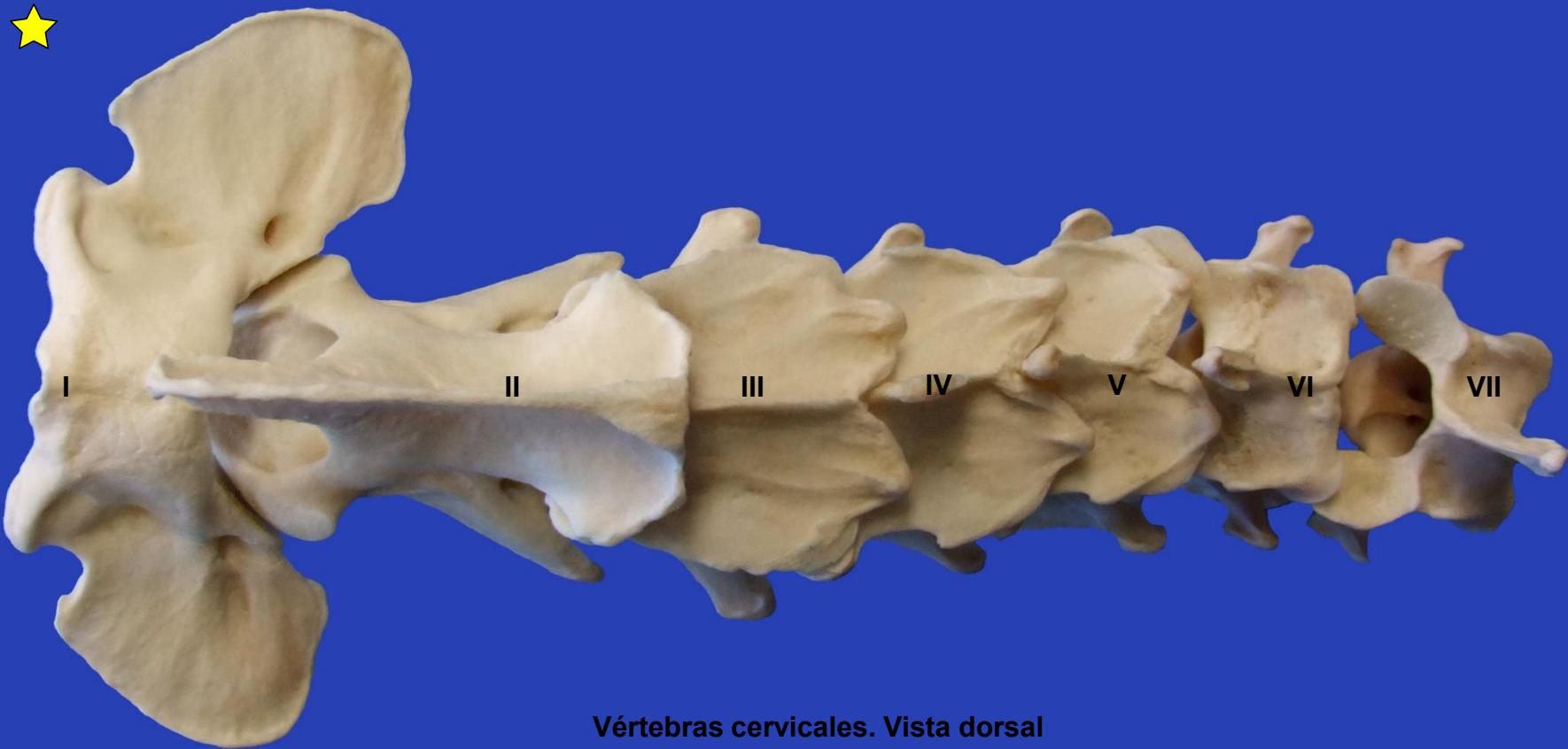
21

24

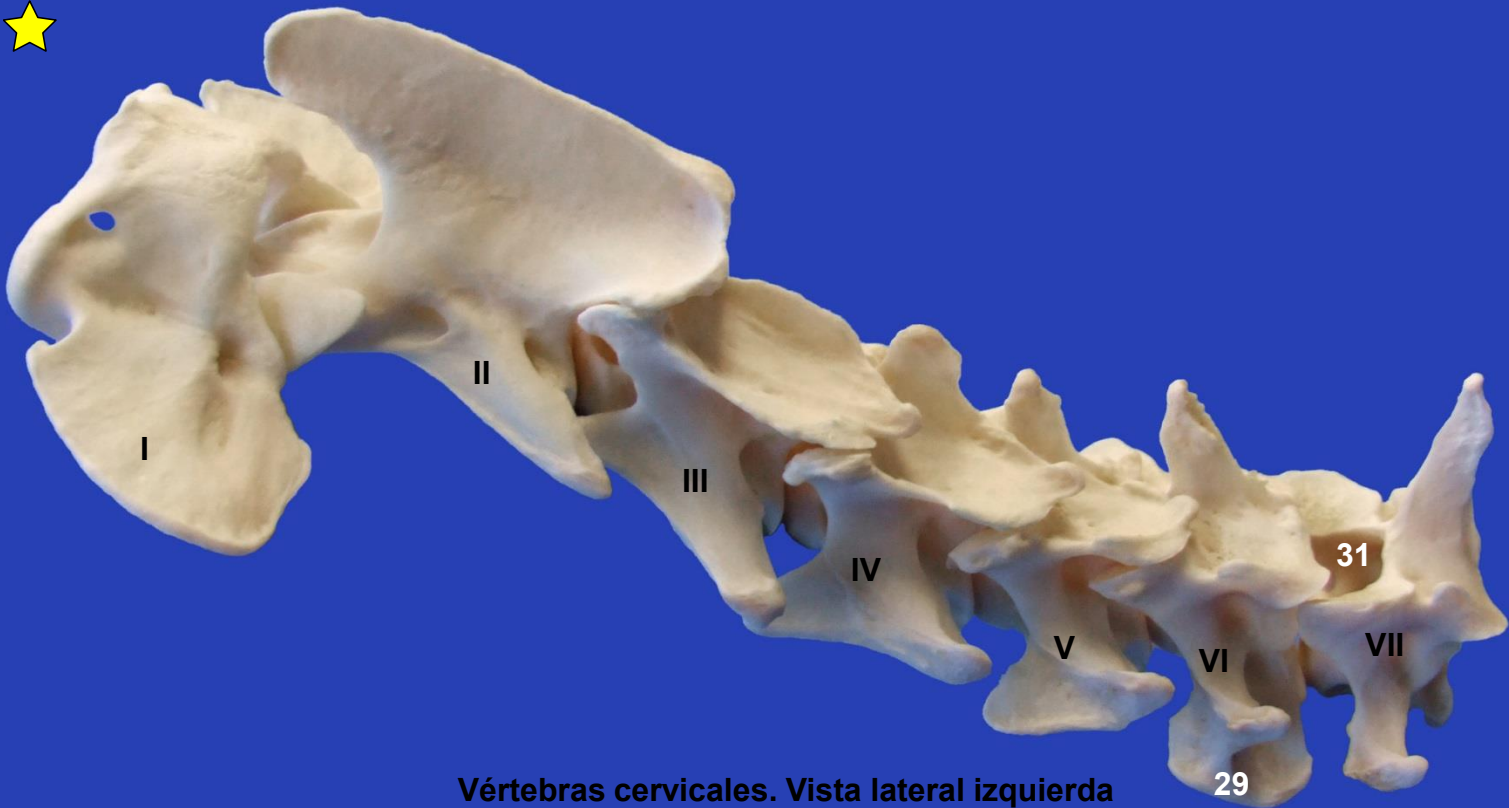21

23

Axis. Vista caudal



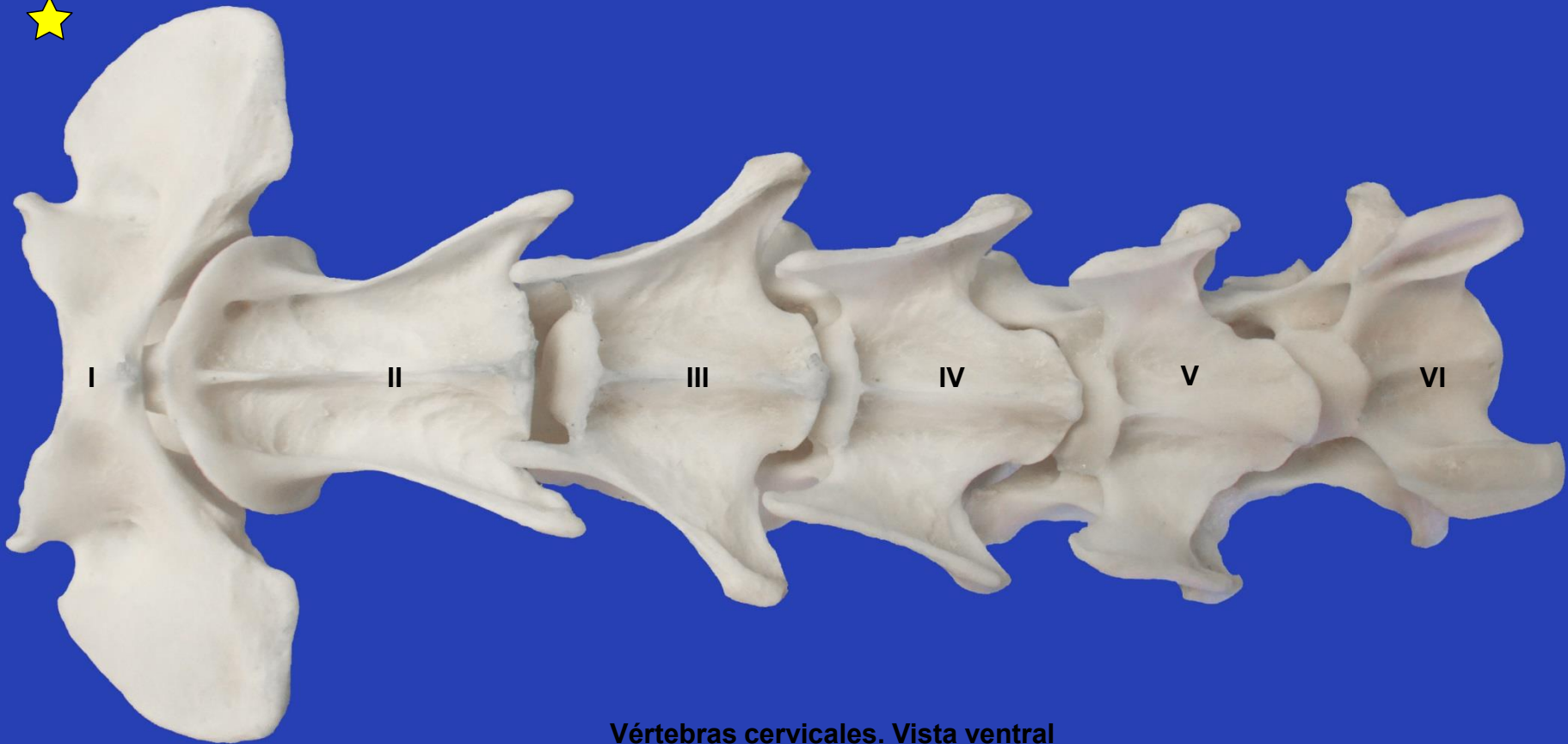
Vértebras cervicales. Vista dorsal



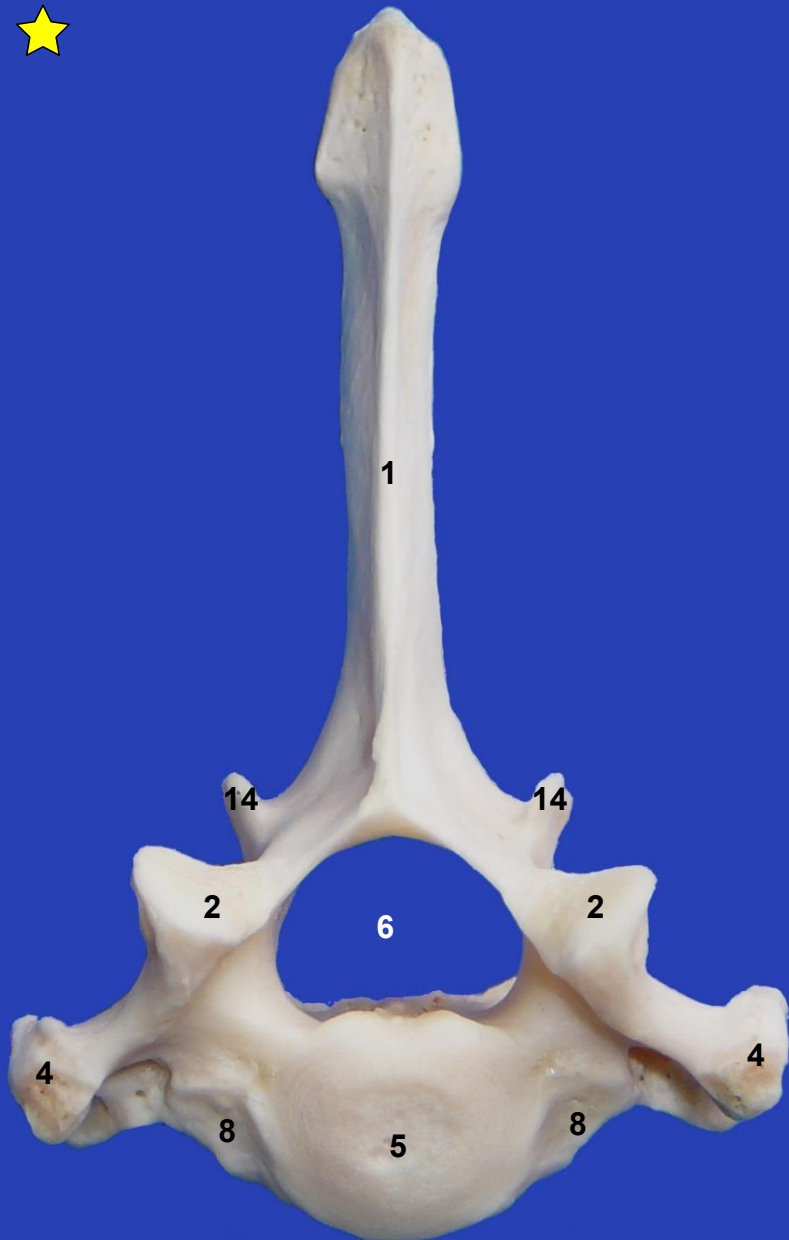
Vértebras cervicales. Vista lateral izquierda

29

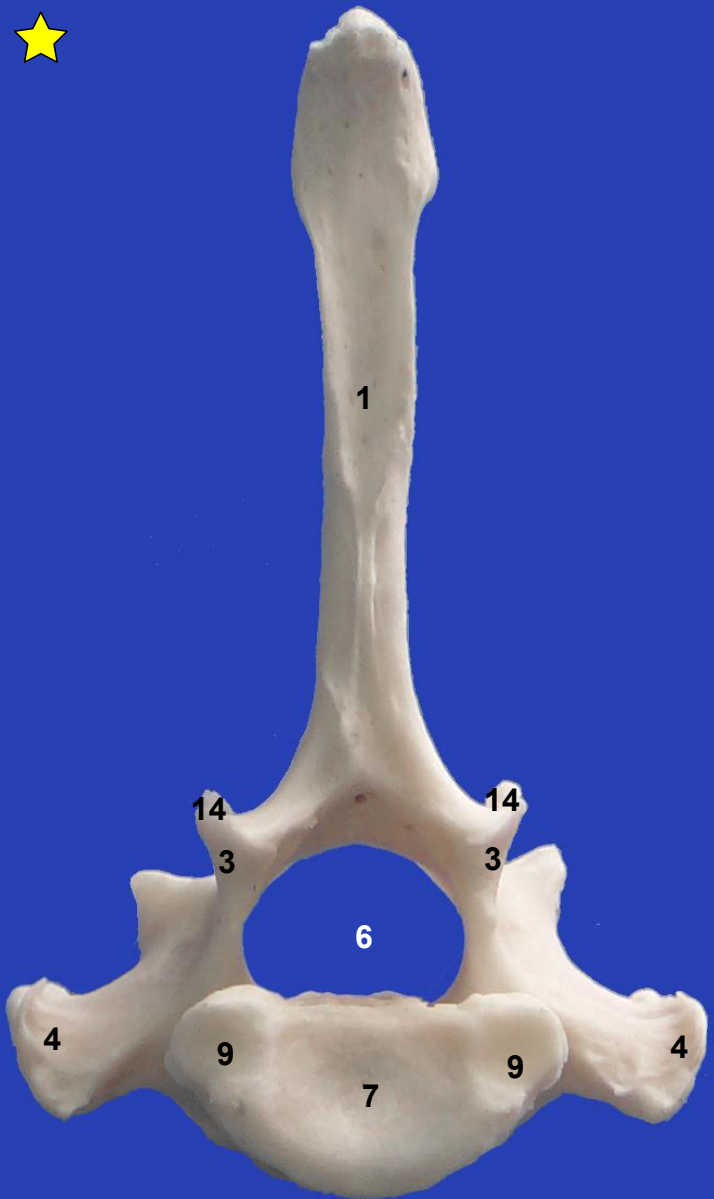
31



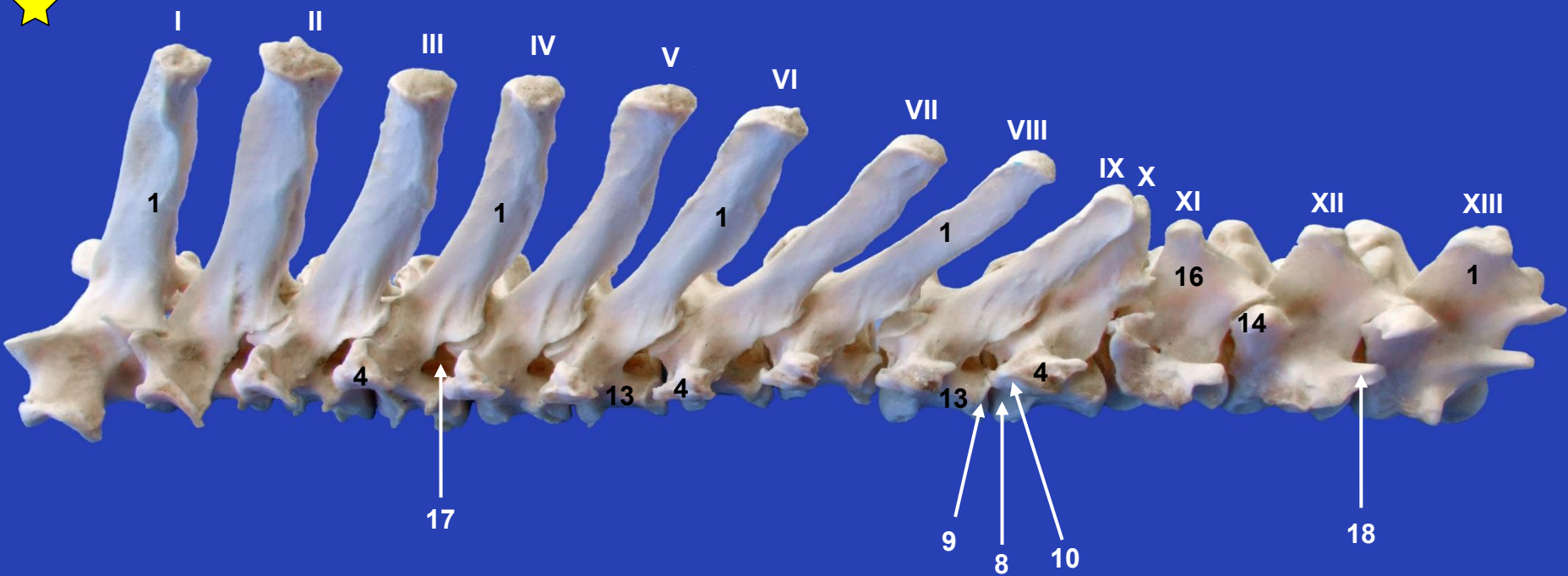
Vértebras cervicales. Vista ventral



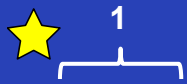
Vértebra torácica. Vista craneal




Vértebra torácica. Vista caudal



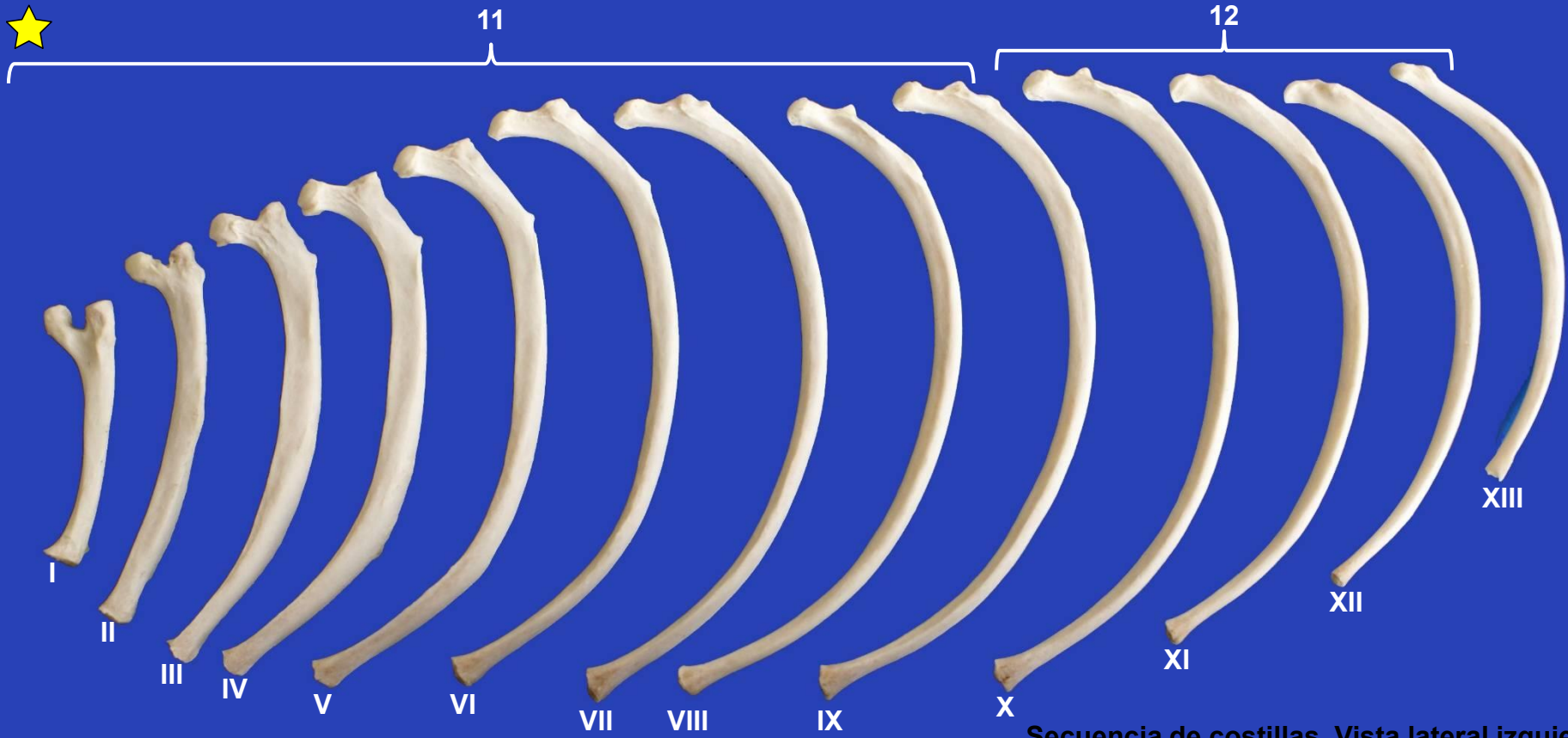
Vértebras torácicas. Vista lateral izquierda



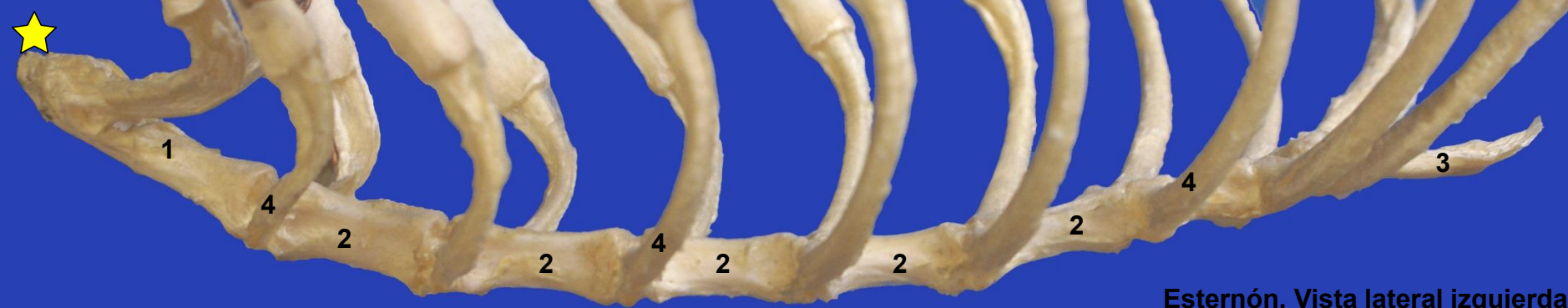
Costilla. Vista lateral



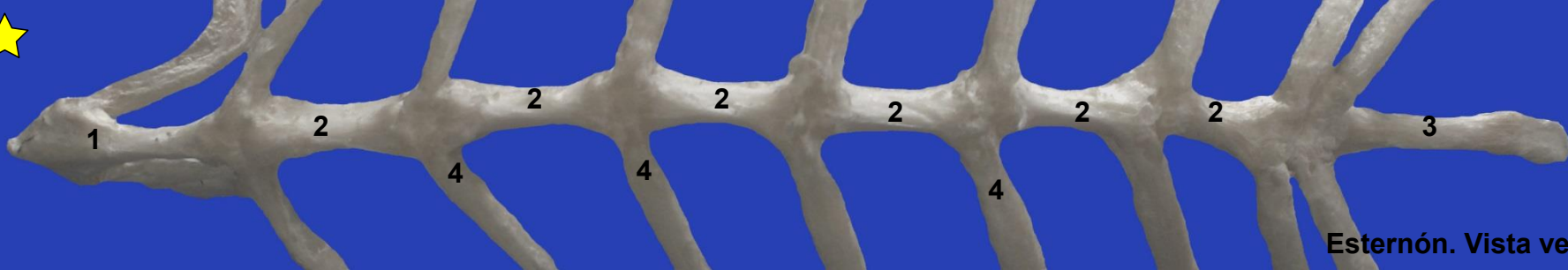
Costilla. Vista medial



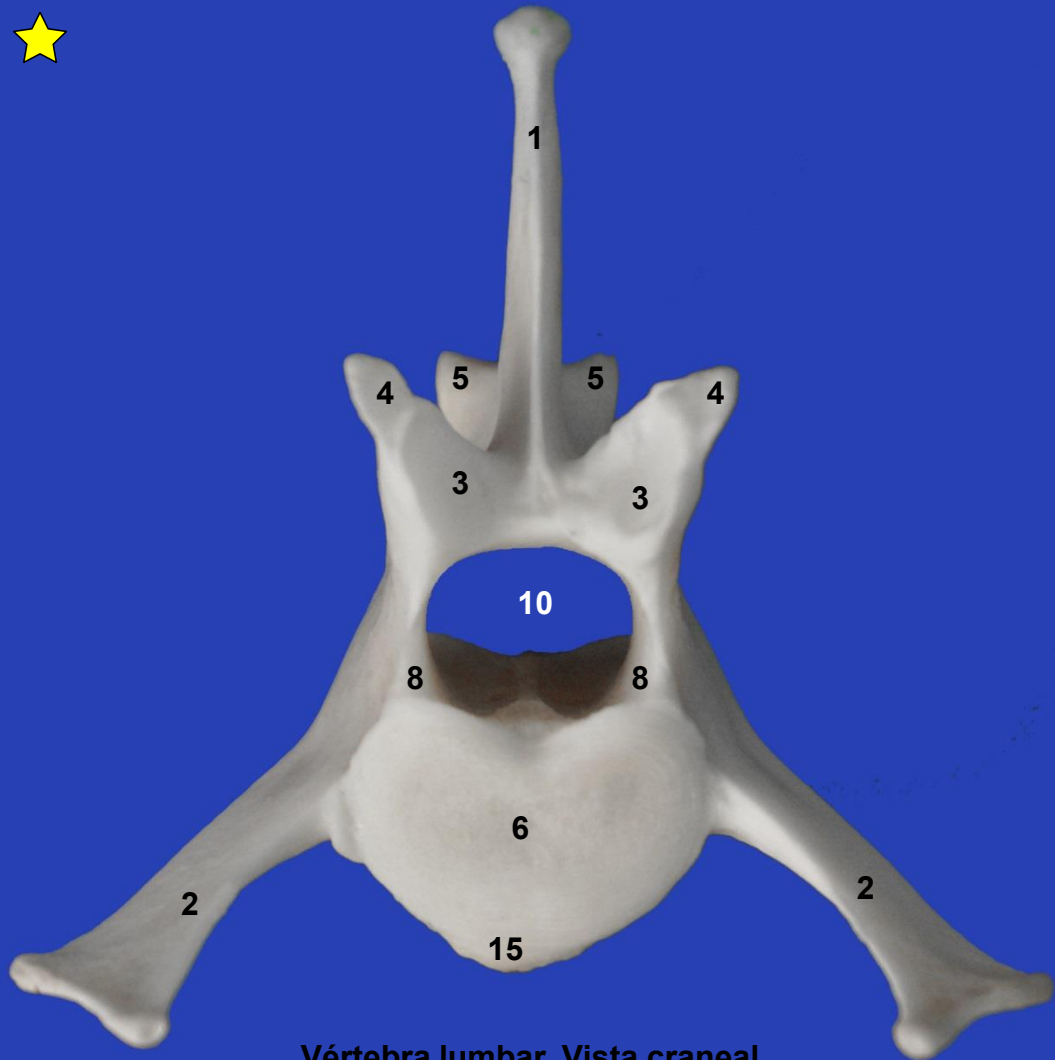
Secuencia de costillas. Vista lateral izquierda



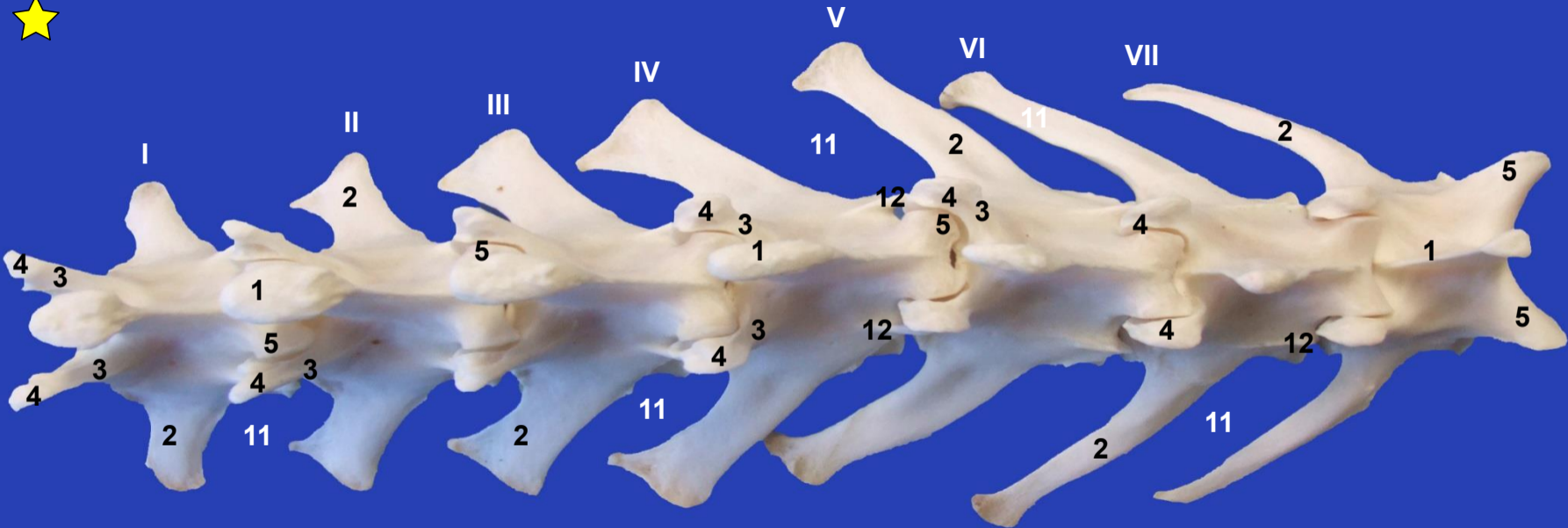
Esternón. Vista lateral izquierda



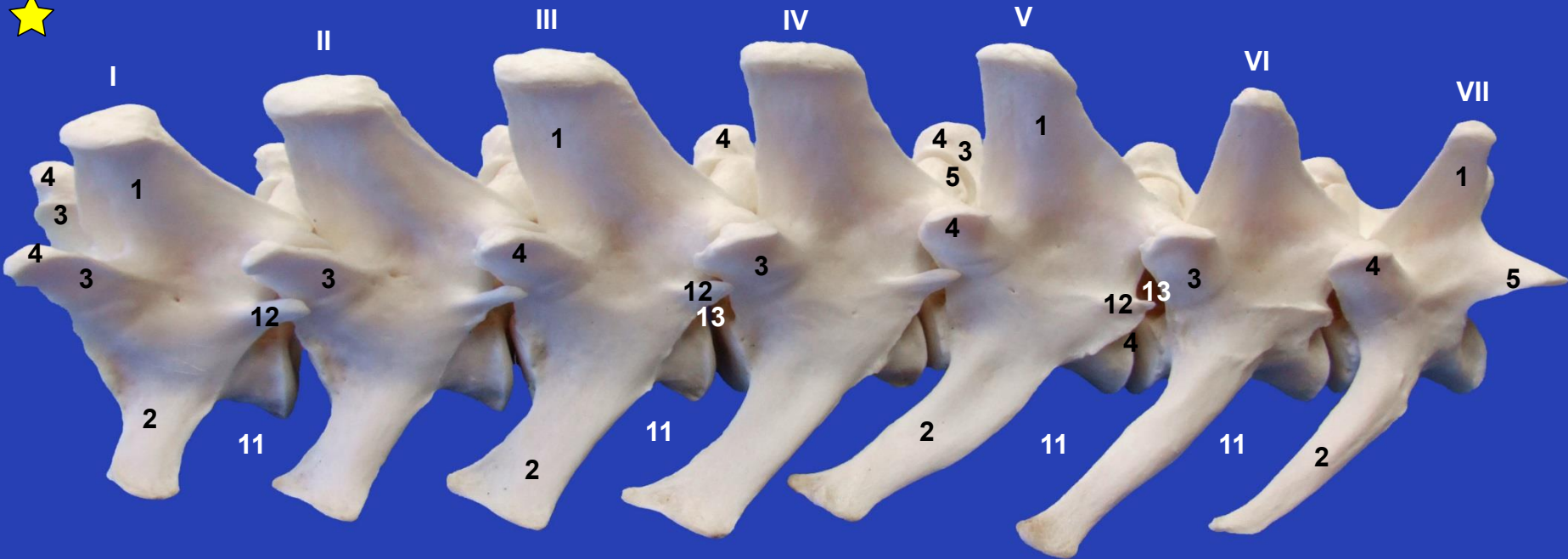
Esternón. Vista ventral



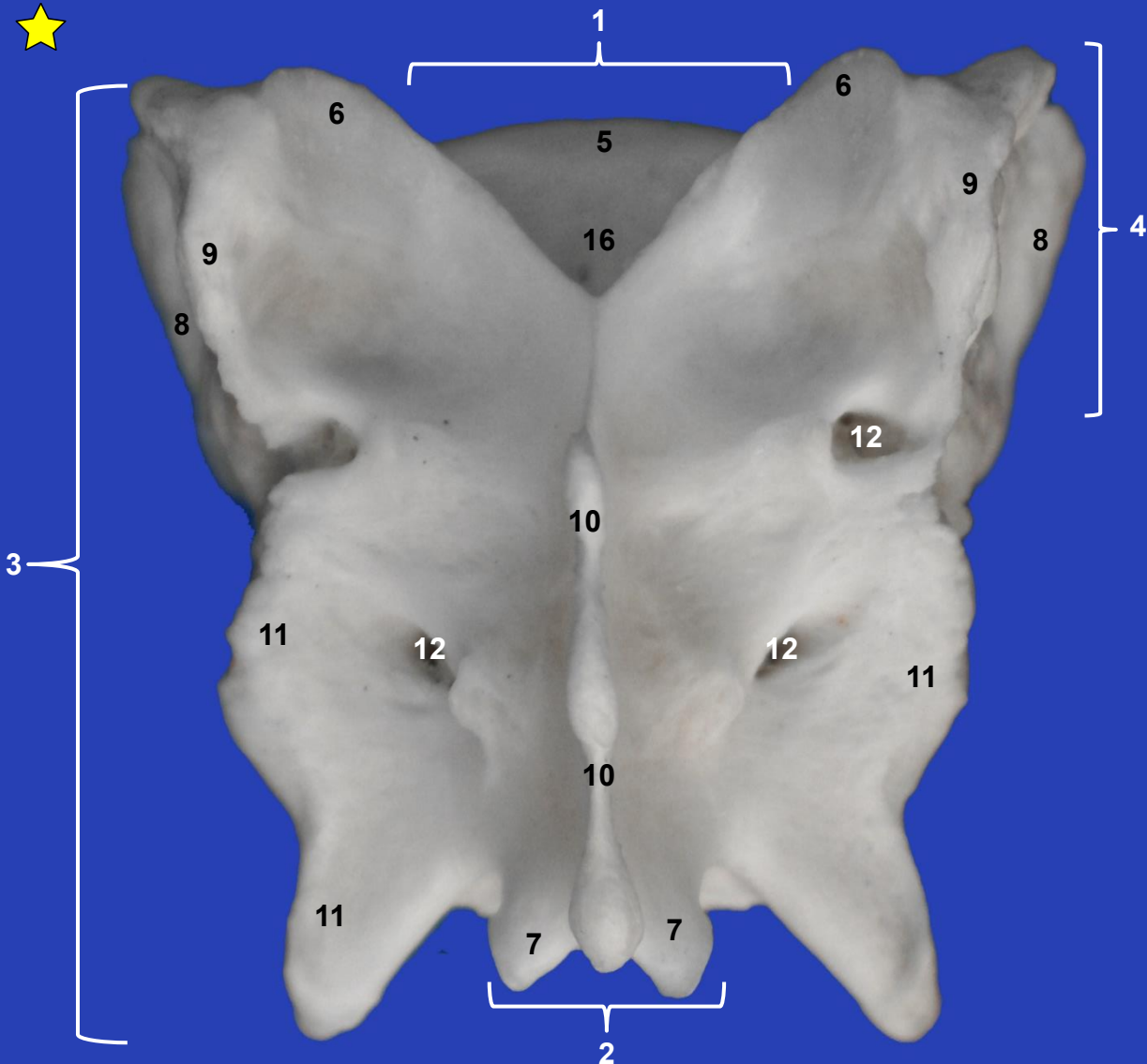
Vértebra lumbar. Vista craneal



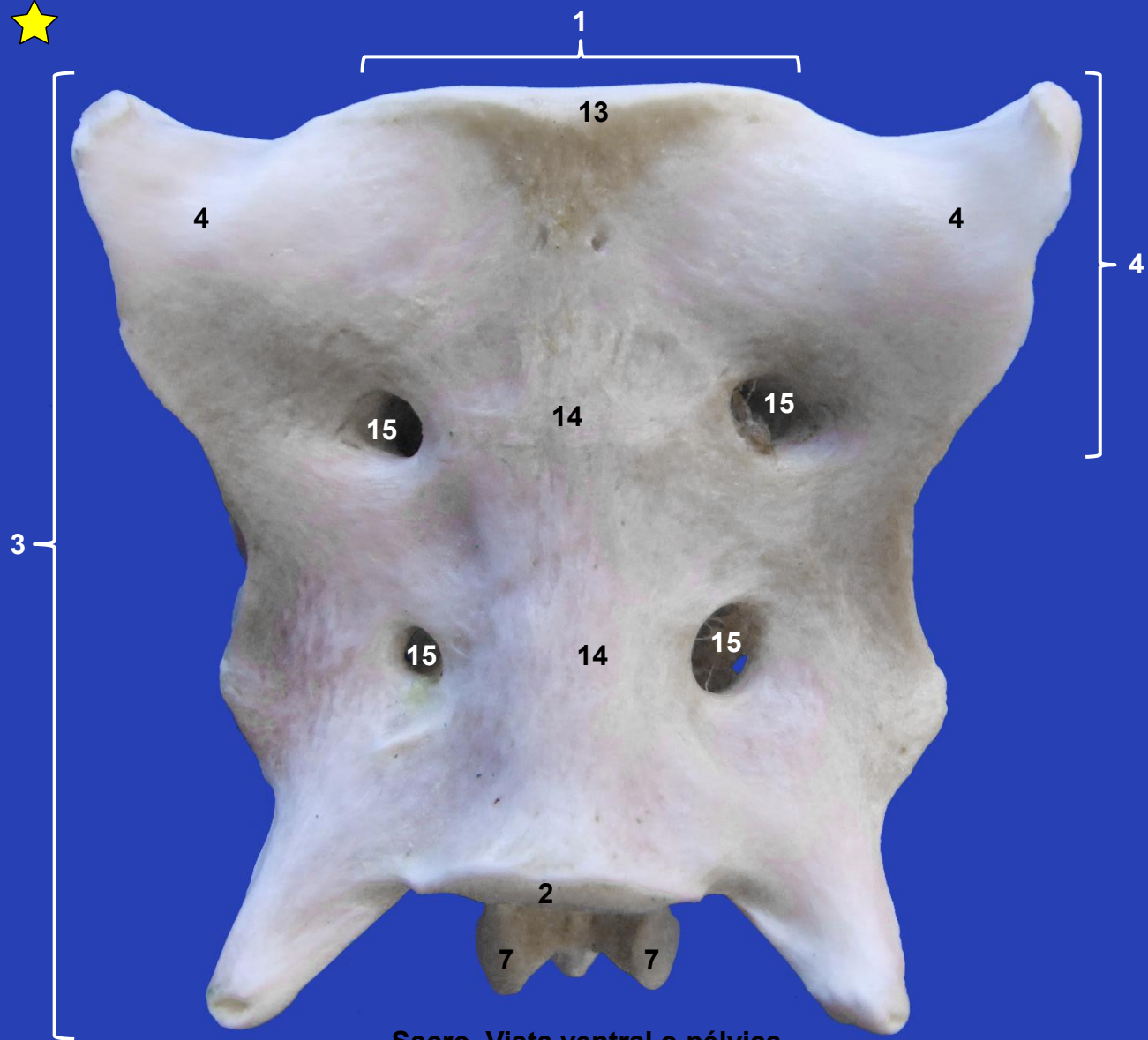
Vértebras lombares. Vista dorsal



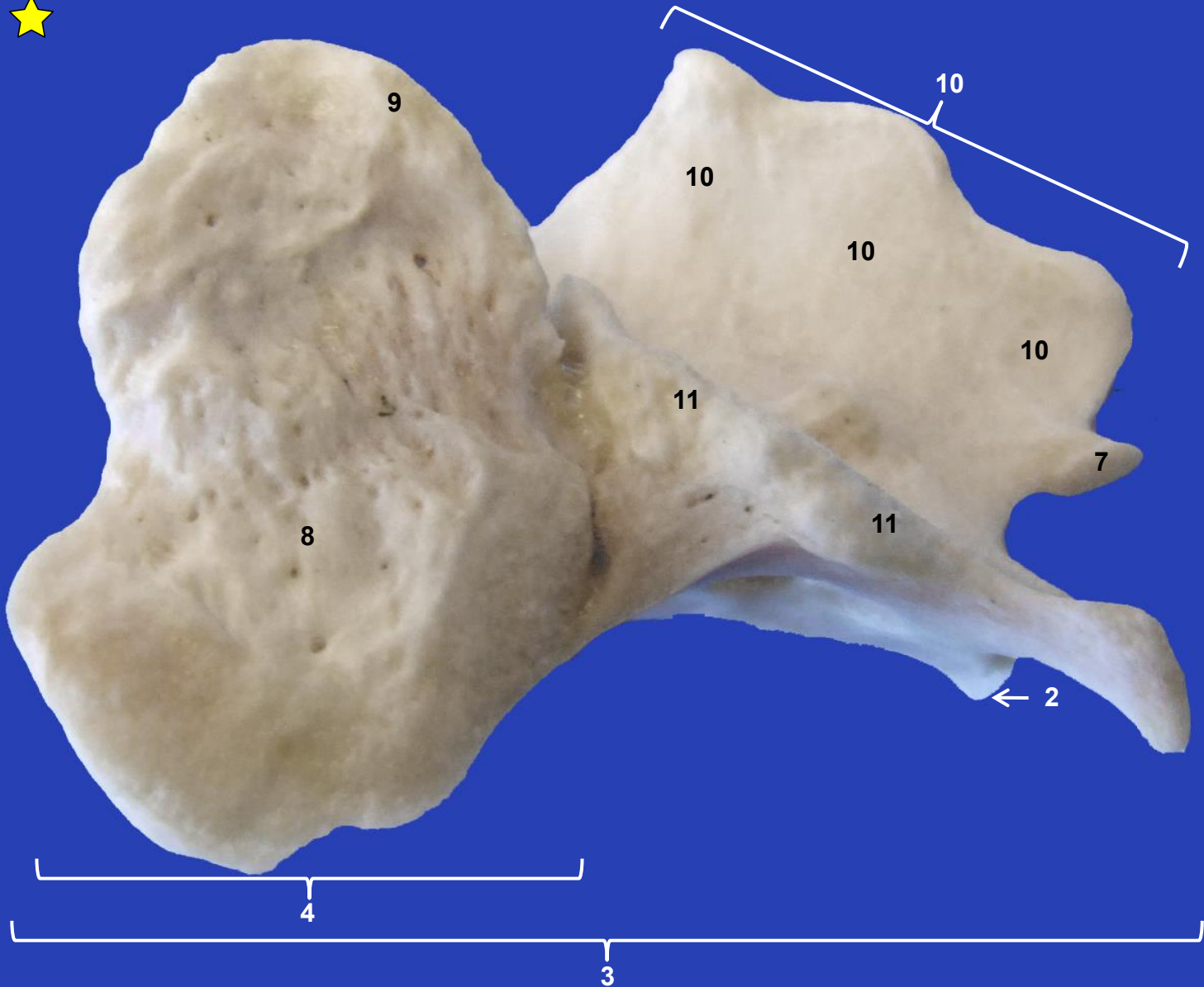
Vértebras lumbares. Vista laterodorsal izquierda



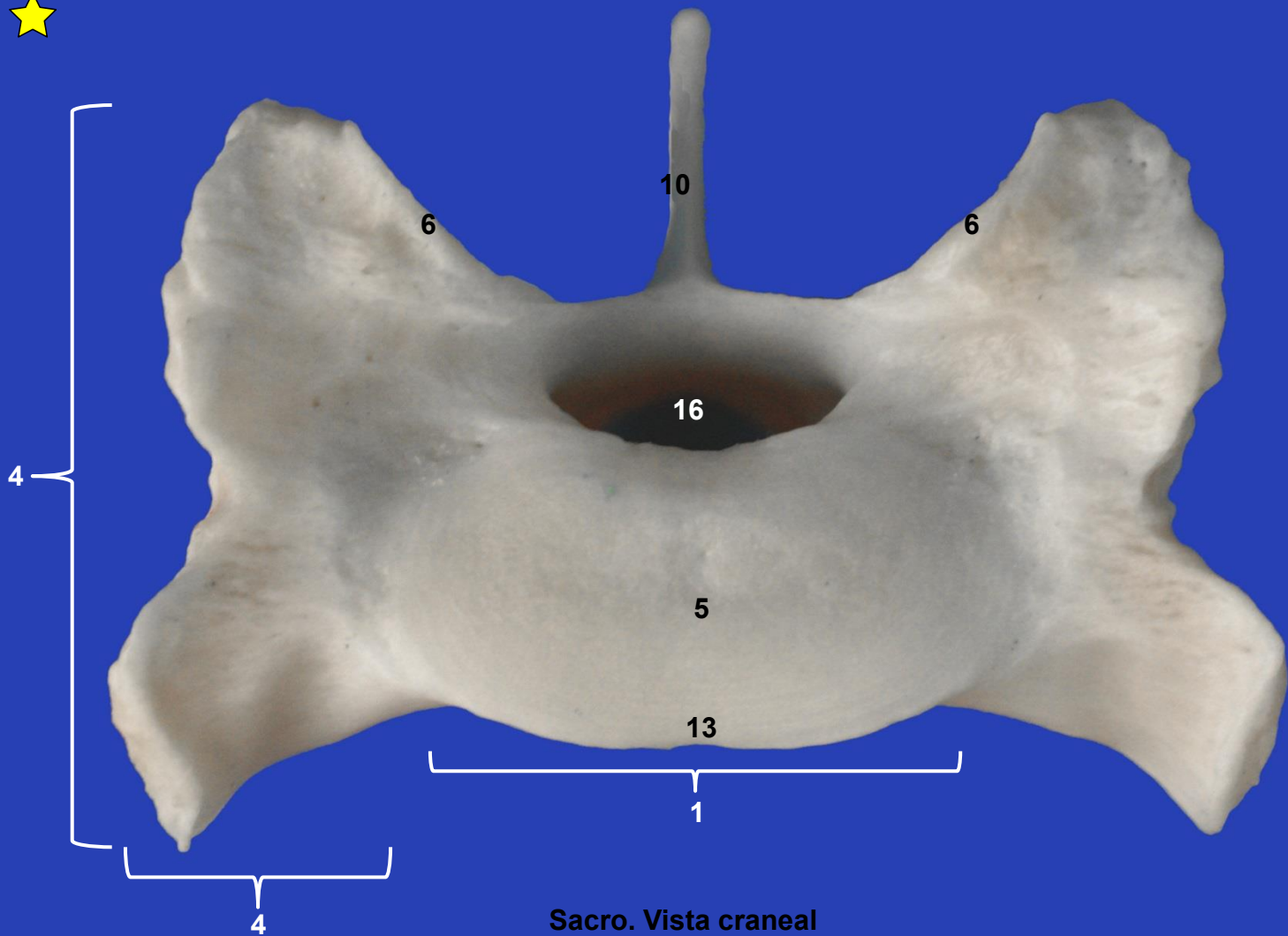
Sacro. Vista dorsal

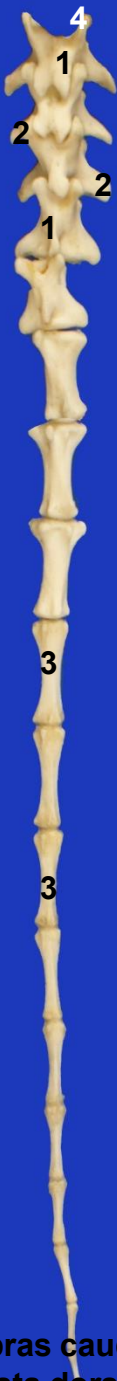

Sacro. Vista ventral o pélvica



Sacro. Vista lateral izquierda





**Vértebras caudales.
Vista dorsal**