

Técnico de centros de recuperación, reproducción y reintroducción de fauna salvaje

Anatomía

Prof. Dr. Ignacio de Gaspar Simón
Sección Departamental de Anatomía y Embriología
Facultad de Veterinaria
U.C.M.
igaspars@uclm.es

@idegaspar

Características anatómicas generales diferenciales de las aves con respecto a mamíferos.



Aparato Locomotor

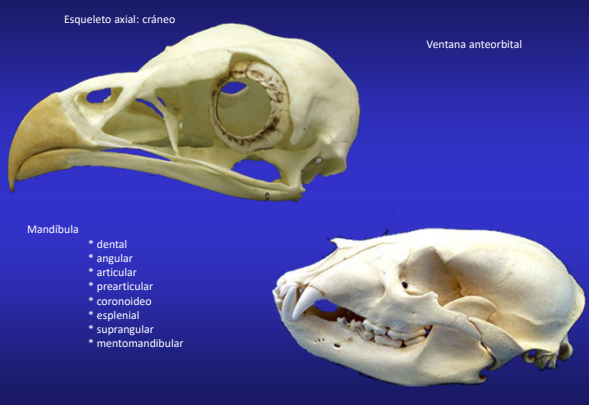
Consideraciones generales



Aparato locomotor

Esqueleto axial: cráneo

Ventana anteorbital

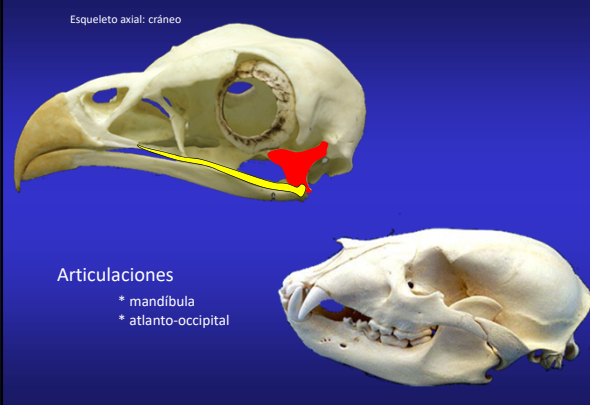


Mandíbula

- * dental
- * angular
- * articular
- * prearticular
- * coronideo
- * esplenial
- * suprangular
- * mentomandibular

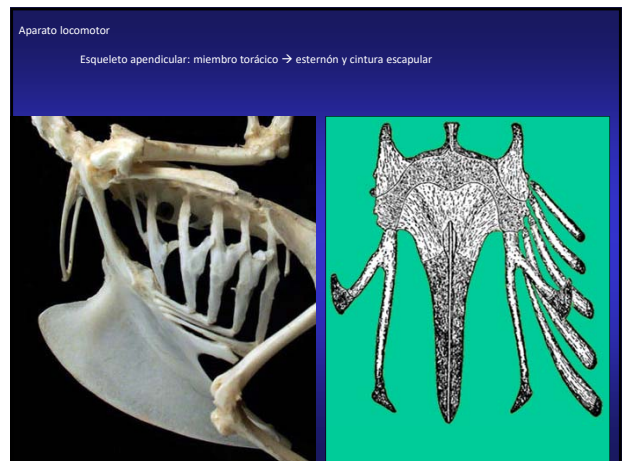
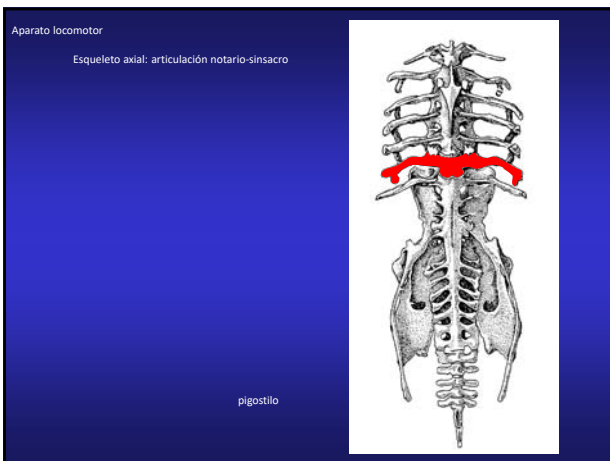
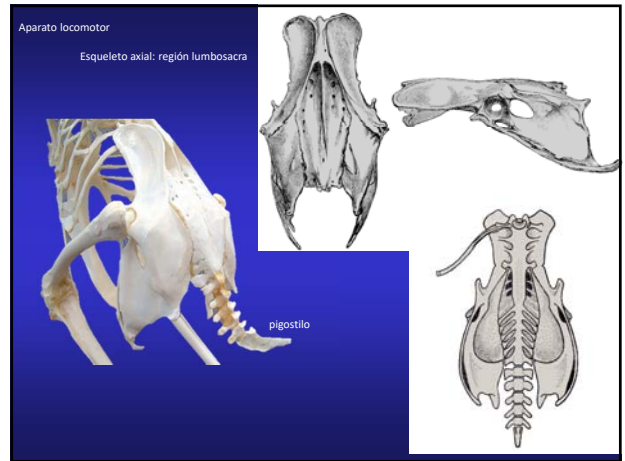
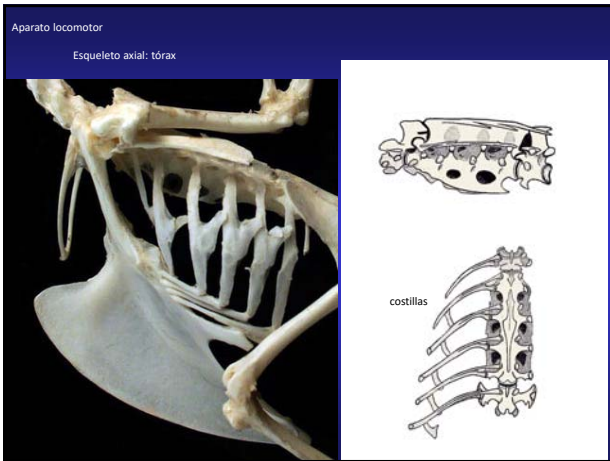
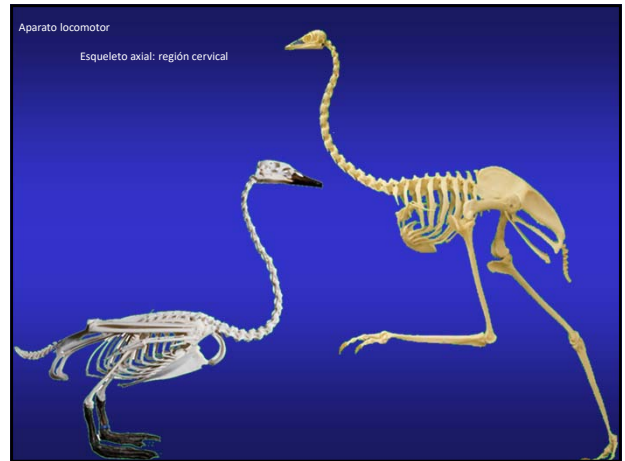
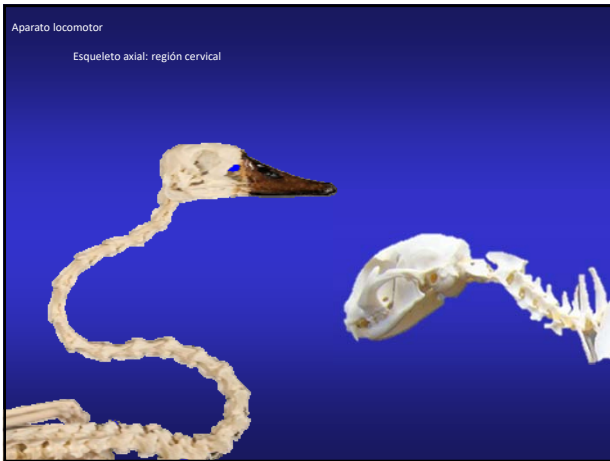Aparato locomotor

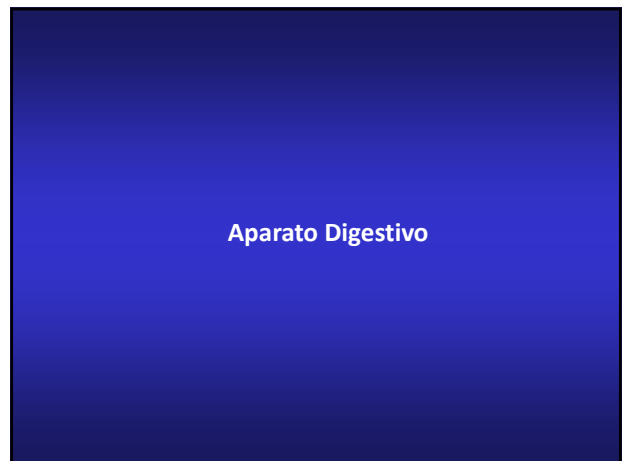
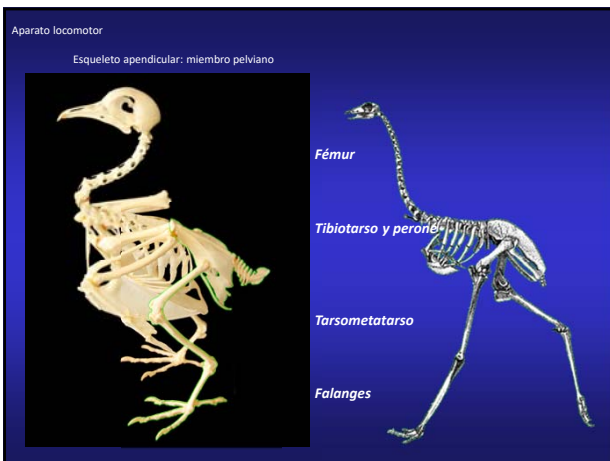
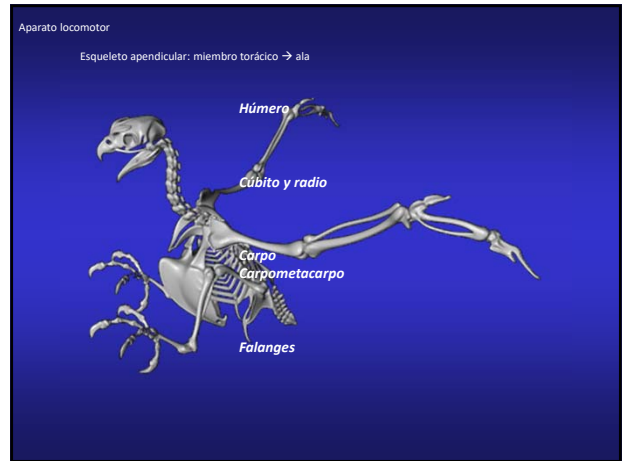
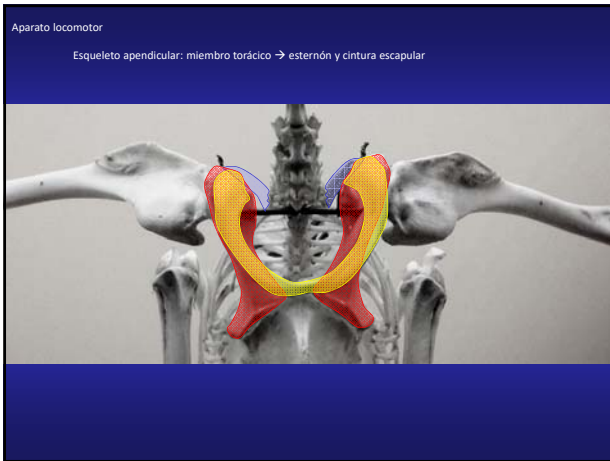
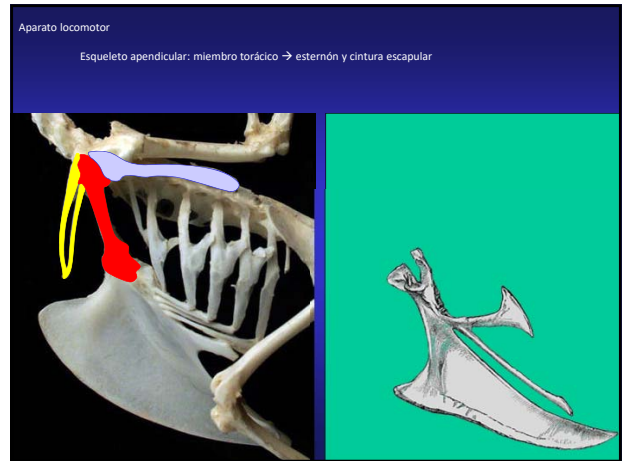
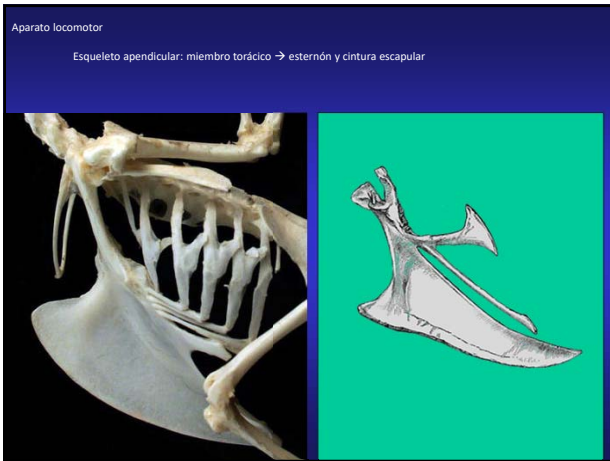
Esqueleto axial: cráneo

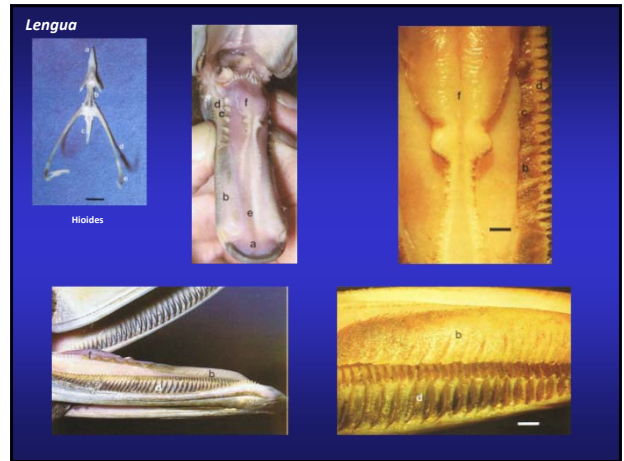
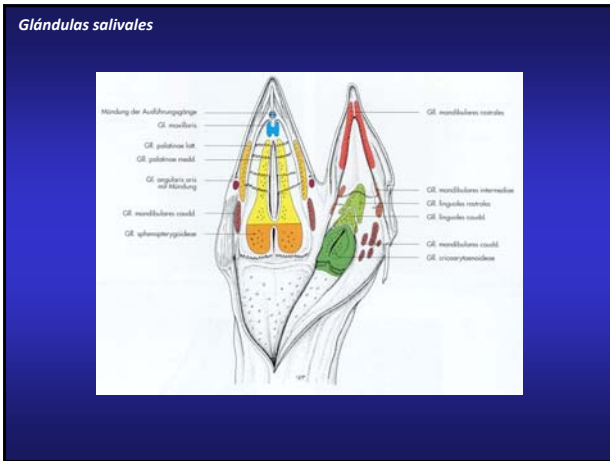
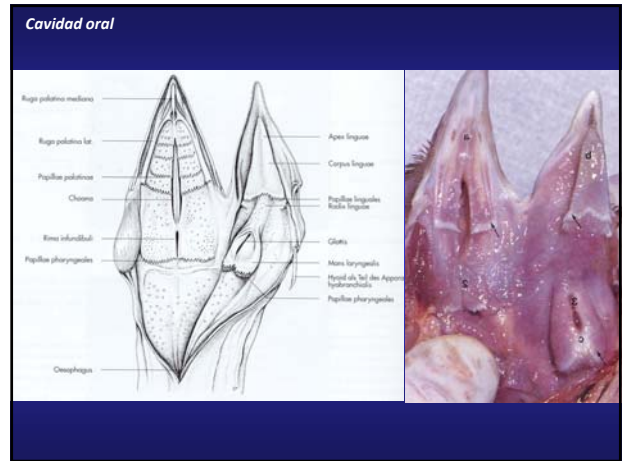
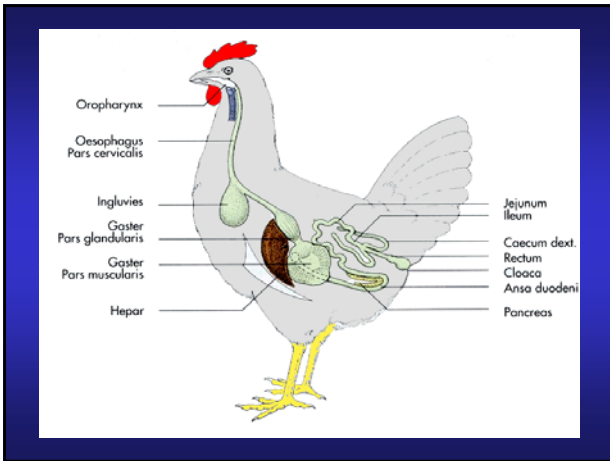


Articulaciones

- * mandíbula
- * atlanto-occipital







Saco esofágico y saco oral

Pinzón montano pardo



Avutarda australiana






Fragata real

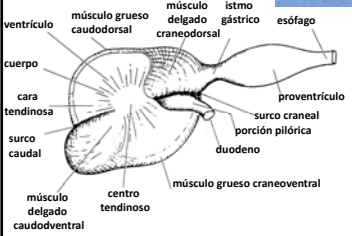



Urogallo de las artemisas




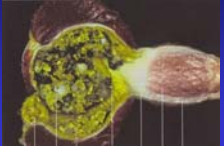
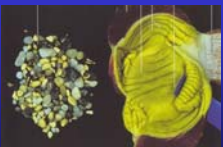
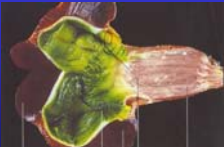
Estómago



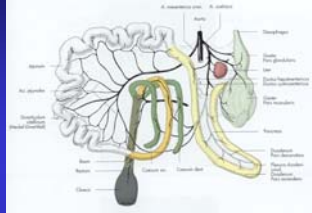


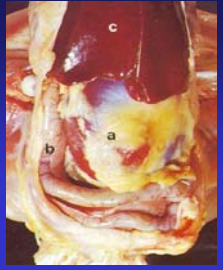



Estómago

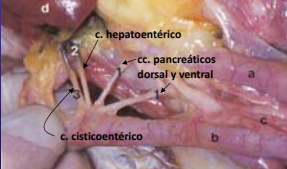





Intestino

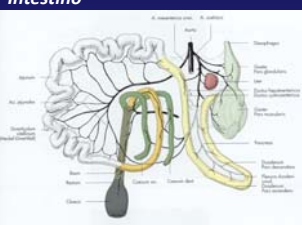





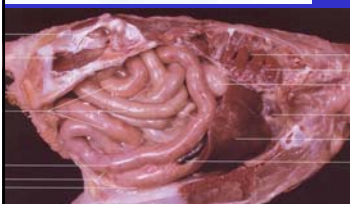





Intestino




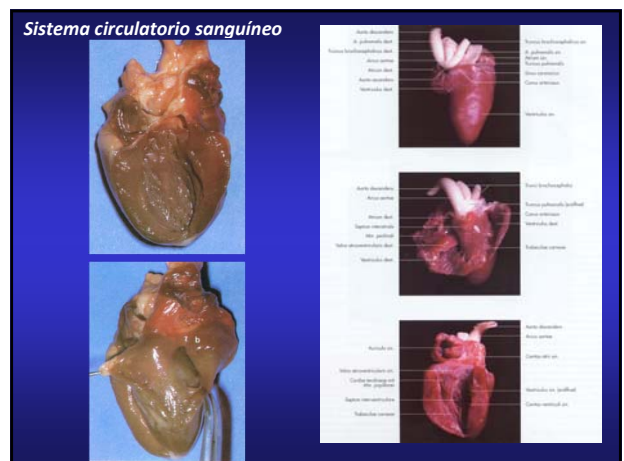
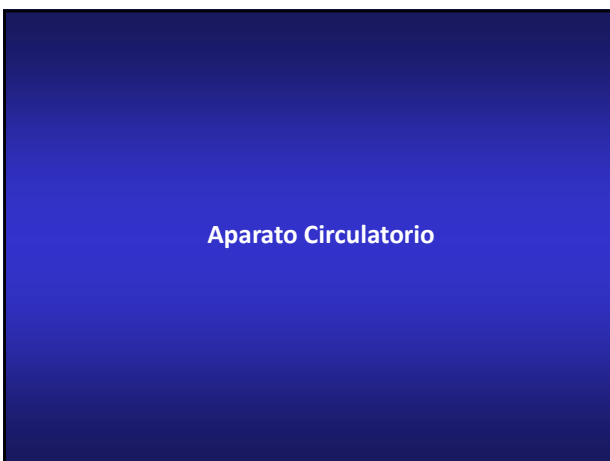
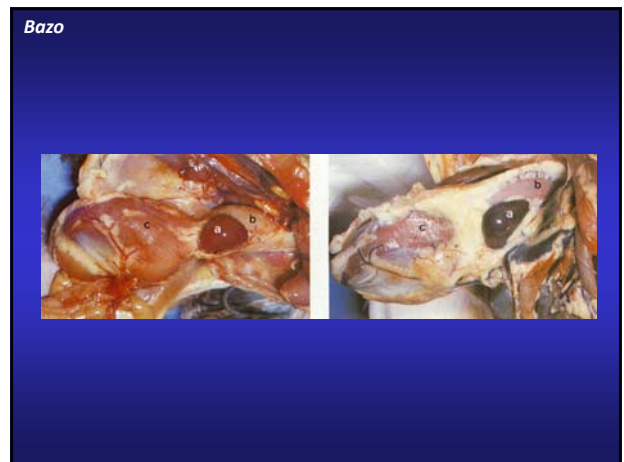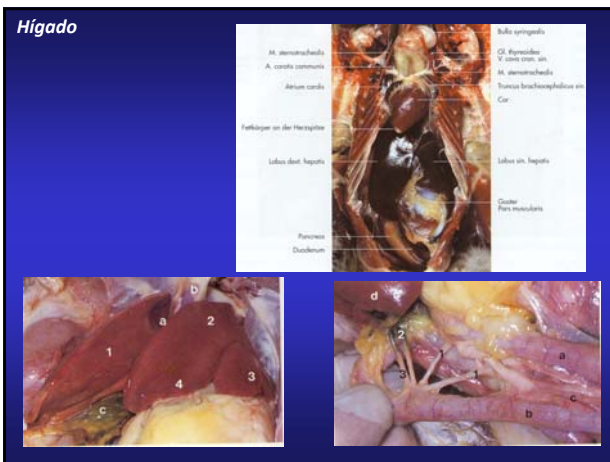
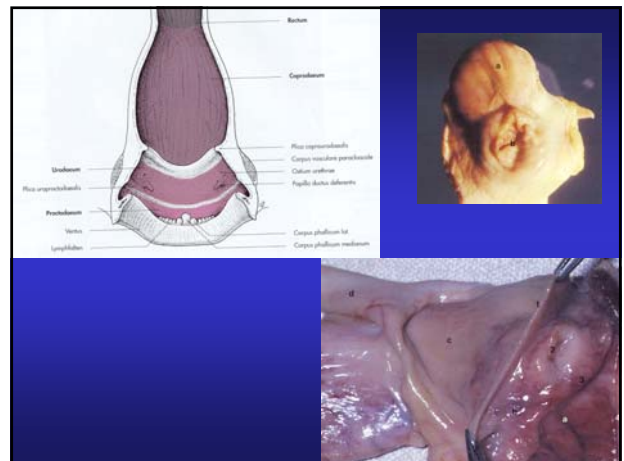

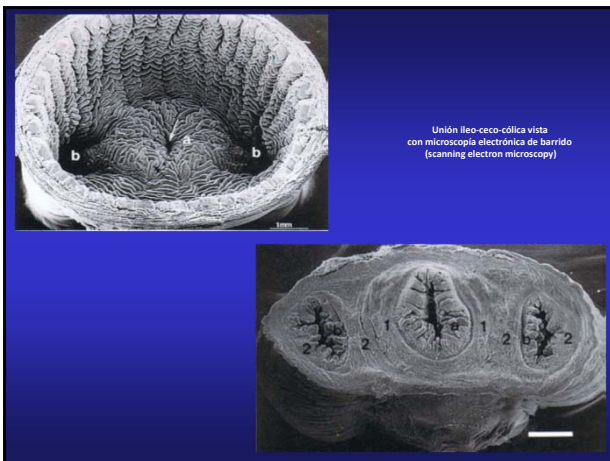
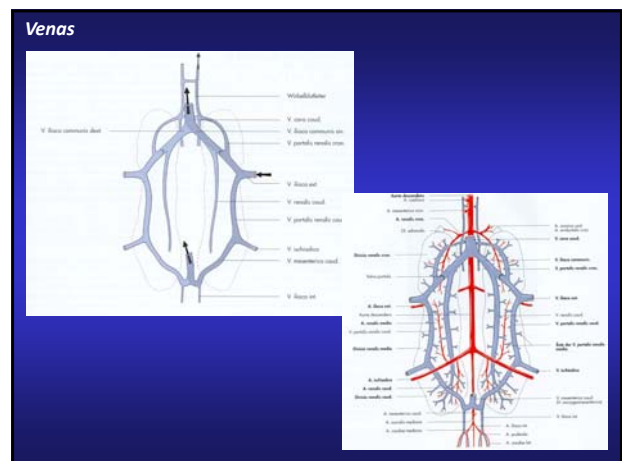
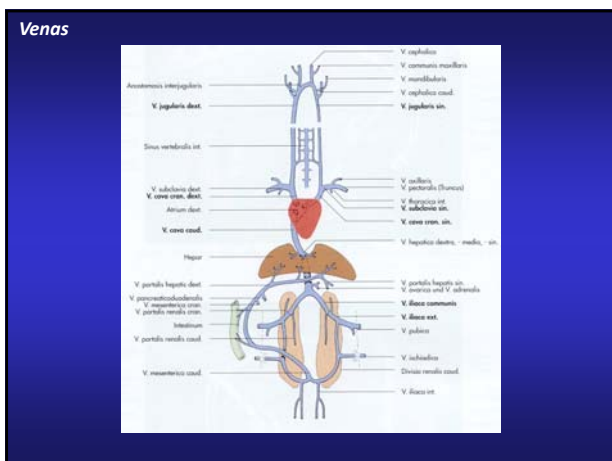
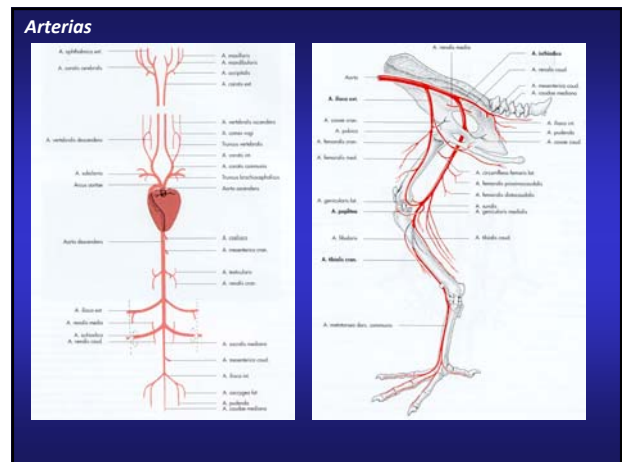
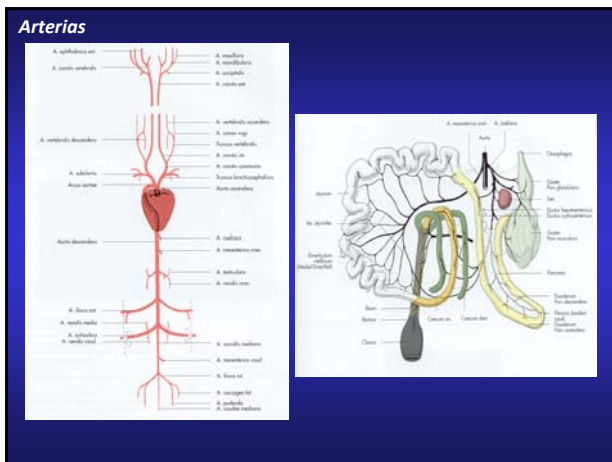
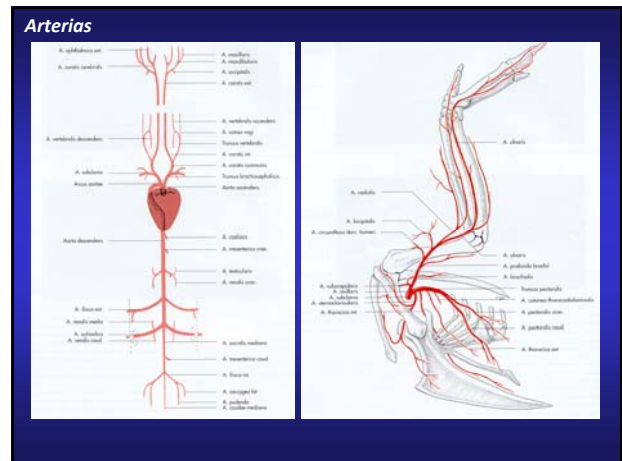


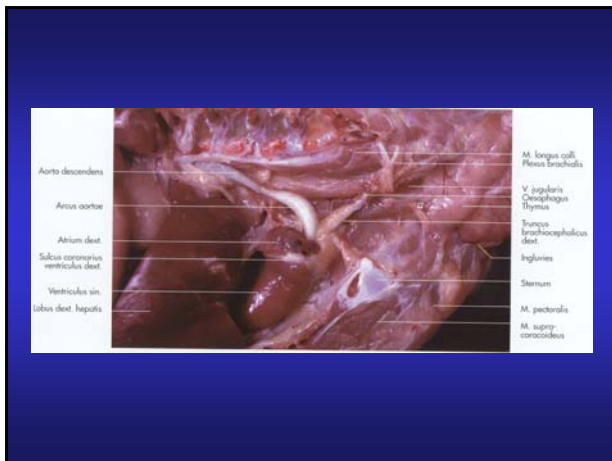

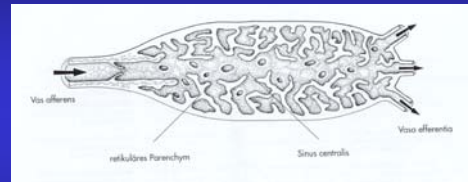
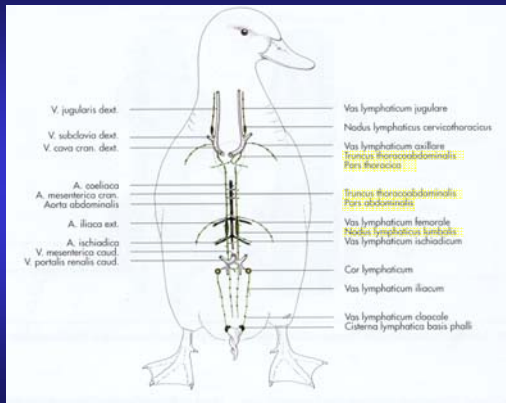
McLelland, J. Anatomy of the avian cecum. In: *Function of the Avian Cecum* (E. J. Braun and G. E. Duker, eds.). Proc. First International Avian Cecal Symposium, Grand Marais, Minnesota, August 1988. *J. Exp. Zool., Suppl.* 3: 2-9.



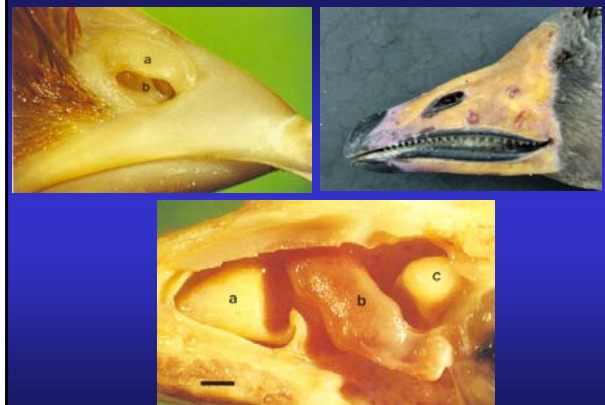



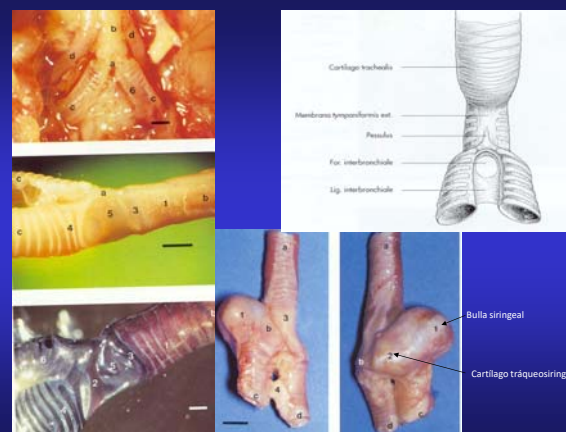
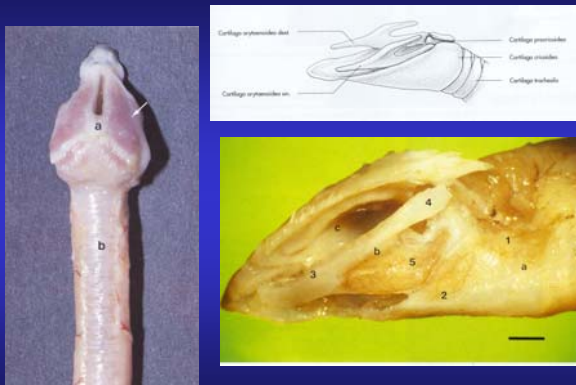
Sistema circulatorio linfático

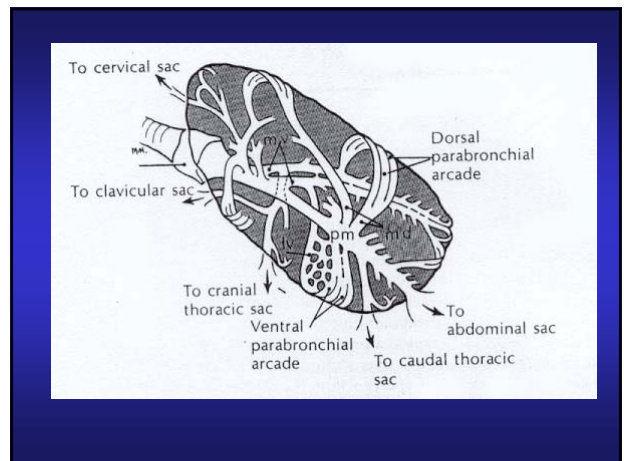
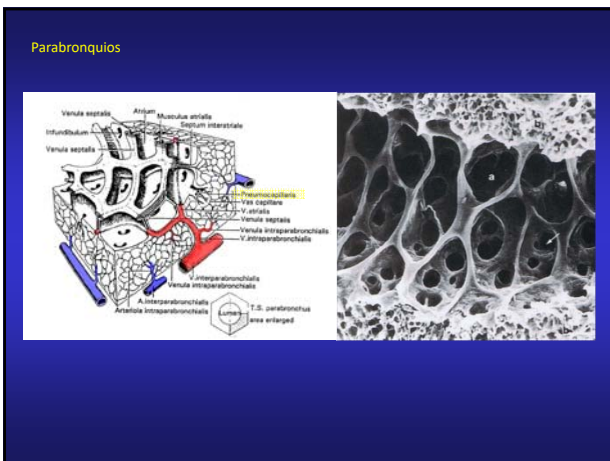
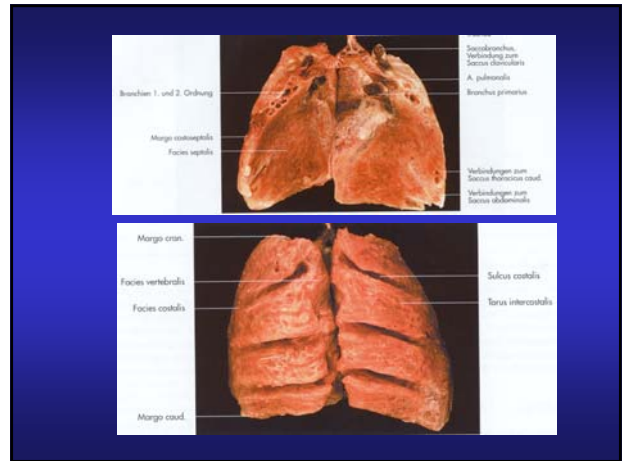
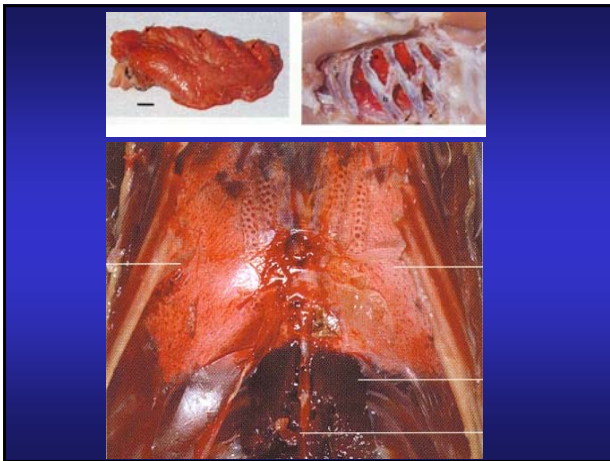
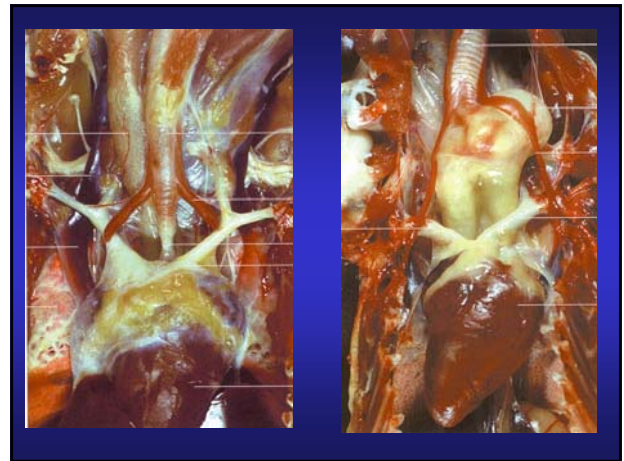
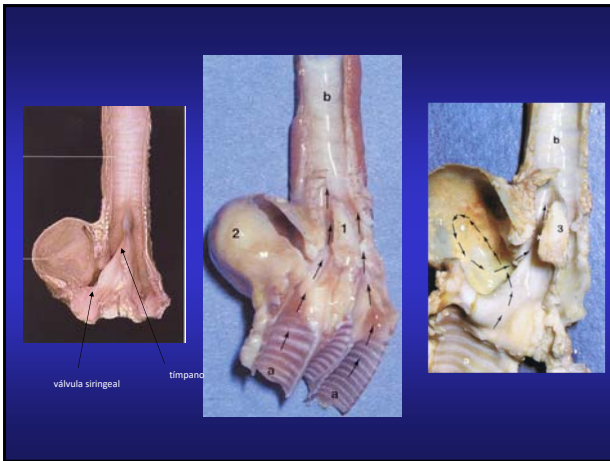

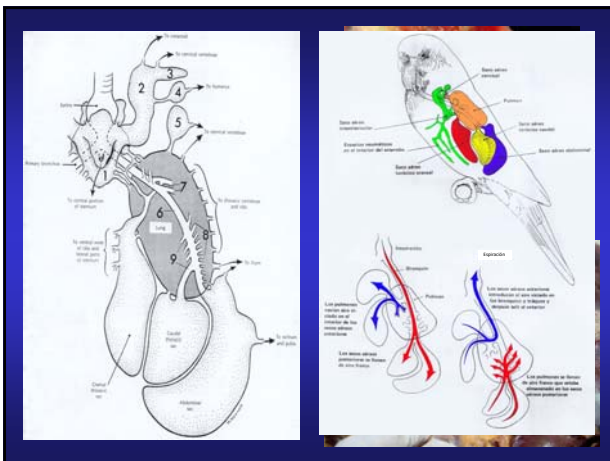
Aparato Respiratorio



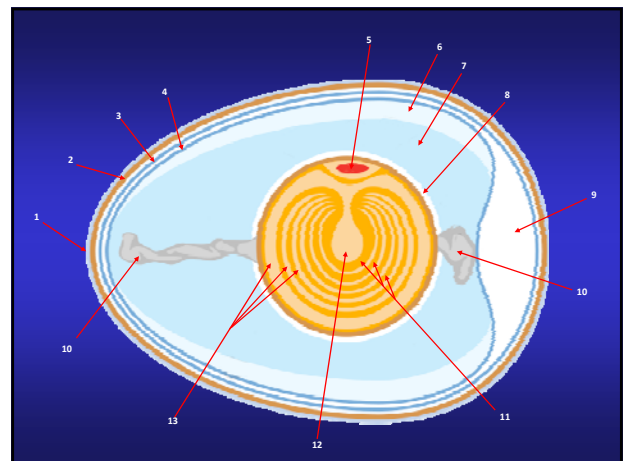
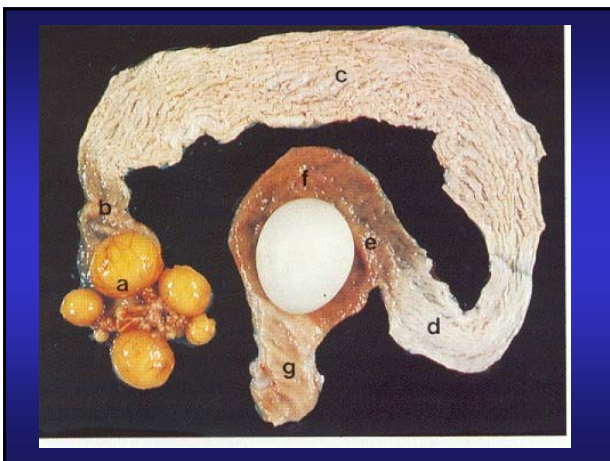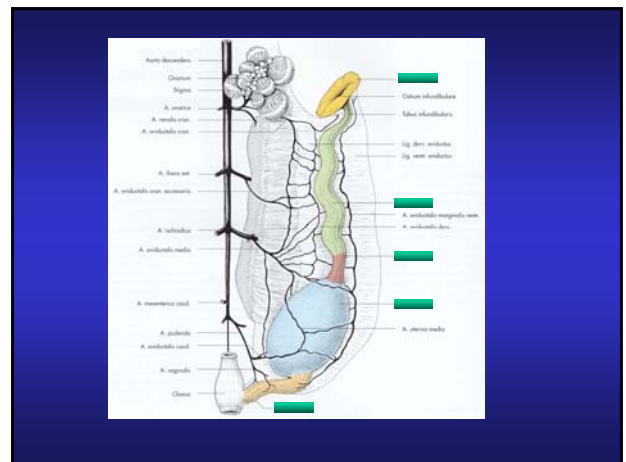
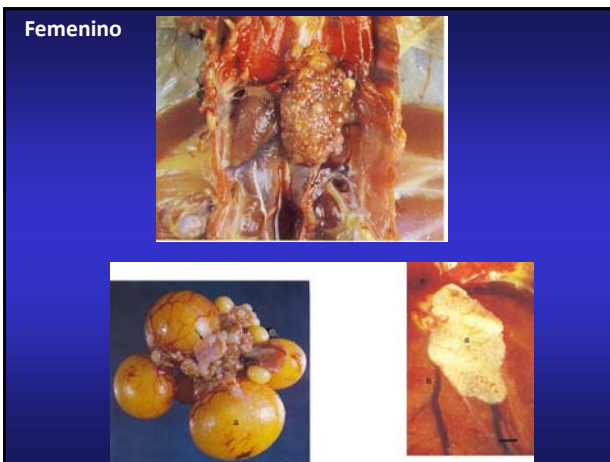Musculatura laríngica

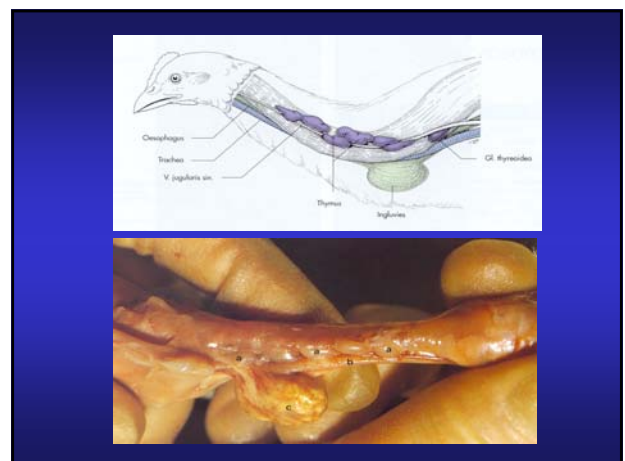
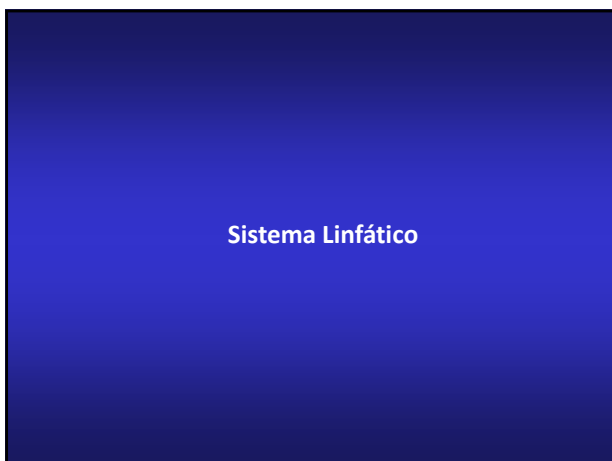
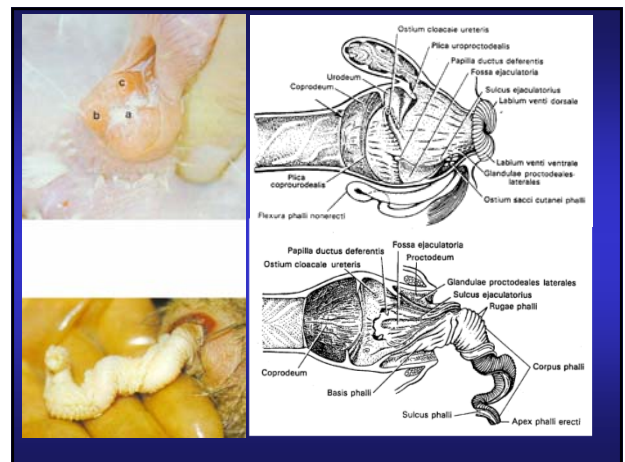
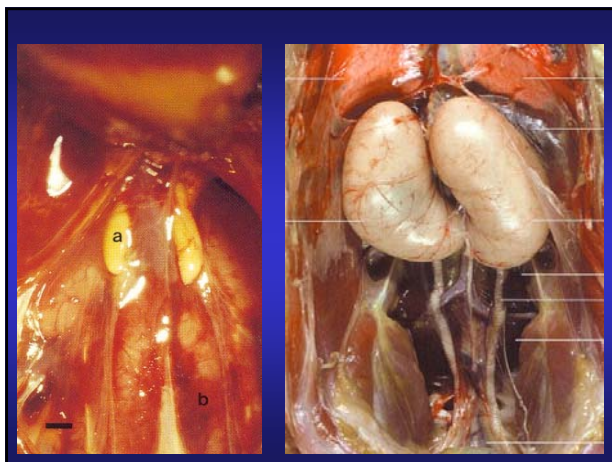
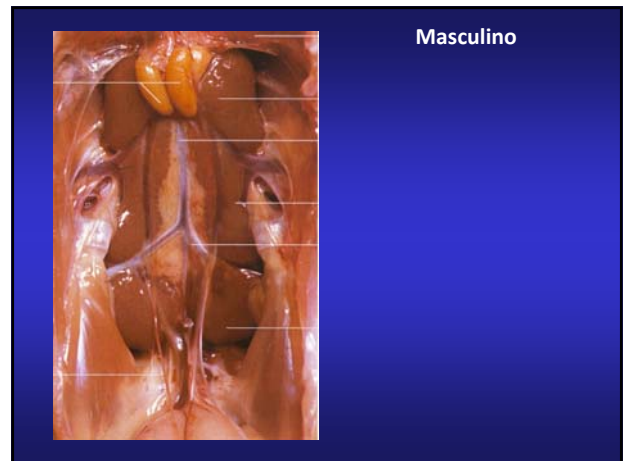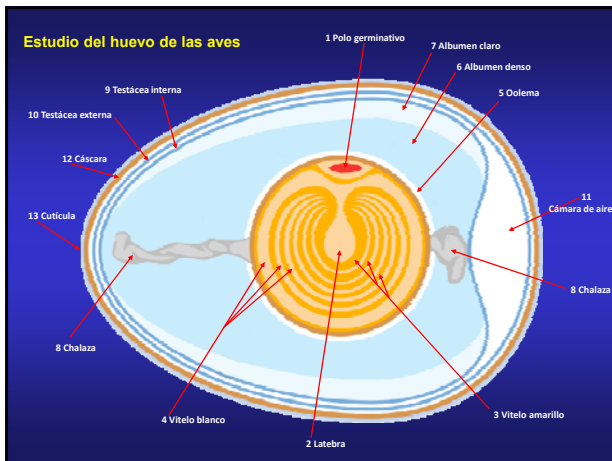


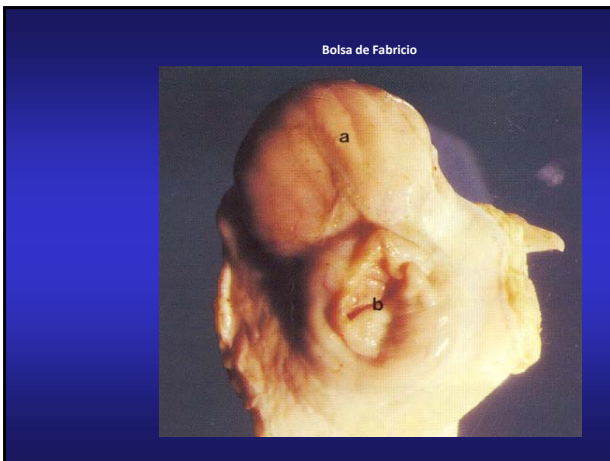




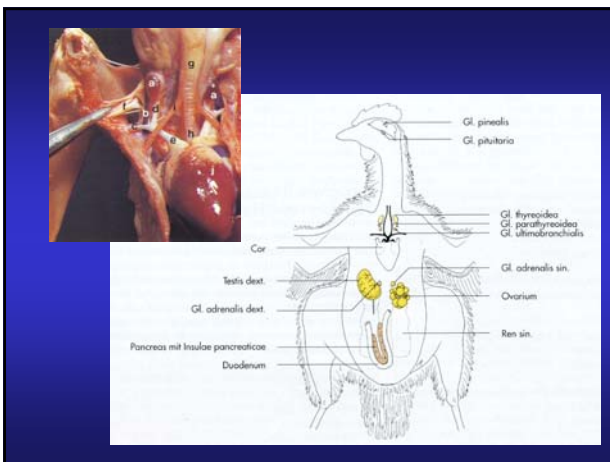
Sistema Urogenital



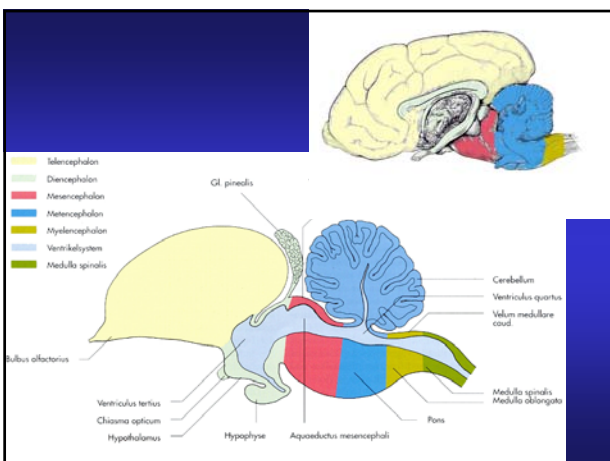




Sistema Endocrino



Sistema nervioso



Órgano de la visión

