


available at www.sciencedirect.comjournal homepage: www.elsevier.com/locate/steroids

Steroids and receptors in canine mammary cancer

Juan C. Illera^{a,*}, Maria D. Pérez-Alenza^b, Ana Nieto^d, Maria A. Jiménez^b, Gema Silvan^a, Susana Dunner^c, Laura Peña^b

^a Department of Animal Physiology, Facultad de Veterinaria, Universidad Complutense de Madrid, Ciudad Universitaria s/n, 28040 Madrid, Spain

^b Department of Animal Medicine, Surgery and Pathology, Facultad de Veterinaria, Universidad Complutense de Madrid, Ciudad Universitaria s/n, 28040 Madrid, Spain

^c Department of Animal Production, Facultad de Veterinaria, Universidad Complutense de Madrid, Ciudad Universitaria s/n, 28040 Madrid, Spain

^d Banco de líneas celulares de Granada, Centro de Investigaciones Biomédicas del Campus de Ciencias de la Salud de Granada, C/Avda. del Conocimiento s/n, Granada 18100, Spain

ARTICLE INFO

Article history:

Received 6 September 2005

Received in revised form 7

November 2005

Accepted 9 November 2005

Published on line 2 May 2006

Keywords:

Hormones

Receptors

Inflammatory mammary carcinoma

Malignant mammary tumors

Canine

ABSTRACT

The aims of this study were to investigate the serum and tissue content of androgens and estrogens in canine inflammatory mammary carcinomas (IMC) as well as in non-inflammatory malignant mammary tumors (MMT), and assessed the immunoeexpression of estrogen and androgen receptors using immunohistochemistry. Profiles for the androgens dehydroepiandrosterone (DHEA), androstenedione (A4), and testosterone (T), and for the estrogens 17 β estradiol (E2) and estrone-sulphate (SO4E1) were measured both in tissue homogenates and in serum of MMT and IMC by EIA techniques in 42 non-inflammatory malignant mammary tumors (MMT) and in 14 inflammatory mammary carcinomas (IMC), prospectively collected from 56 female dogs. Androgen receptor (AR) and estrogen receptor alpha (ER α) and beta (ER β) expression was studied using immunohistochemistry (streptavidin–biotin–peroxidase method) in samples of 32 MMT and 14 IMC, and counted by a computer image analyzer. IMC serum and tissue levels of androgens were significantly higher than MMT levels. Tissue content of estrogens was also significantly higher in IMC than in MMT. Serum values of SO4E1 were significantly higher in IMC, but serum levels of E2 were significantly lower in IMC compared to MMT cases. Medium-high androgen receptor intensity was observed in 64.28% of IMC and 40.62% of MMT. No important differences were found between ER α expression in IMC (100% negative) and MMT (90% negative). ER β and AR were intensely expressed in highly malignant inflammatory mammary carcinoma cells. To our knowledge, this is the first report relative to AR immunohistochemistry in canine mammary cancer and to estrogens or androgens in serum of dogs with benign or malignant mammary tumors.

© 2006 Elsevier Inc. All rights reserved.

1. Introduction

Inflammatory breast cancer (IBC) is a rare form of rapidly advancing human mammary cancer, accounting for less than

* Corresponding author at: Dpto. Fisiología Animal, Facultad de Veterinaria, Universidad Complutense de Madrid, Avda. Puerta de Hierro s/n, 28040 Madrid, Spain. Fax: +34 91 394 3864.

E-mail address: jcillera@vet.ucm.es (J.C. Illera).

0039-128X/\$ – see front matter © 2006 Elsevier Inc. All rights reserved.

doi:10.1016/j.steroids.2005.11.007

6% of all mammary cancer diagnoses. A distinct clinical subtype of locally advanced breast cancer, it occurs with or without mammary nodules, and is characterized by a particularly aggressive behaviour and prognosis, with erythema, warmth, and edema of the breast [1,2]. Its histological hallmark is the invasion of dermal lymphatic vessels by neoplastic emboli, which block lymphatic drainage to cause the edema [1,2].

Spontaneous inflammatory mammary cancer (IMC) has also been described in the dog [3] and, recently, in the cat [4]. Both species have been proposed as natural models for human IBC, with a focus towards new therapy approaches [5]. Several similarities have been found between human and canine inflammatory mammary cancer with respect to histopathology, clinical characteristics, and prevalence [3–6]. One purpose of the present study is to establish canine inflammatory mammary cancer as a model of the corresponding human breast cancer.

Our preliminary results [7] described elevated levels of some hormones in tumor homogenates of a small number of samples with IMC, indicating that IMC is an important source of steroids. The participation of hormones in canine mammary tumors has not been extensively studied. One study referred the detection of estrogen alpha and progesterone receptors (ER α and PR) by biochemical and immunohistochemical methods [8,9]. Recently, the immunohistochemical expression of ER β has been demonstrated in both normal and neoplastic mammary glands of the dog [10]. There are no reports concerning the existence of androgen receptors in normal or neoplastic canine mammary glands. The aim of this study was to compare the serum and tissue content of androgens (DHEA, A4, and T) and estrogens (E2 and SO4E1) in inflammatory mammary tumors with levels in non-inflammatory malignant canine mammary tumors, in a large series of cases. The expression of androgen receptors (AR), and estrogen receptors alpha (ER α) and beta (ER β) in IMC cases versus other non-inflammatory malignant mammary tumors was also investigated, using immunohistochemistry.

2. Materials and methods

2.1. Animals

2.1.1. Clinical procedures

Forty female dogs (aged 7–14 years) with non-inflammatory malignant mammary tumors (MMT) and 14 female dogs with inflammatory mammary carcinomas (IMC) (aged 7–14 years) were clinically examined following the protocols established by the Veterinary Teaching Hospital of Madrid. Some of the dogs with IMC were referred cases from practitioners. Ten adult healthy female beagle dogs were used as controls. All dogs with non-inflammatory malignant mammary tumors (MMT) were surgically excised. The diagnostic criteria for inflammatory mammary carcinoma (IMC) were based on clinical features described in dogs [3] and in women [2], and were confirmed by histopathology (Tru-cut biopsy or necropsy). In IMC cases, surgery was not the treatment of election; only palliative therapy with anti-

inflammatories and corticoids was applied. Cytology of vaginal smears was performed in each case to determine the stage of the estrus cycle at sampling. This study was performed with the approval of the Veterinary School Ethics Committee.

2.1.2. Sampling procedure

Sixty-six mammary samples (42 malignant mammary tumors and 14 inflammatory mammary carcinomas) and serum samples, were prospectively collected. Normal mammary gland tissues and serum were obtained from 10 dogs (aged 7–10 years) without a history of mammary or endocrine disorder, by Tru-cut biopsies. Malignant mammary non-inflammatory tumors ($n=42$) were either surgical or necropsy specimens submitted for diagnosis to the Pathology Service of the VTHM. Samples of IMC ($n=14$) were obtained from Tru-cut biopsies or necropsies. In each case, two adjacent fragments of tissue were separated and processed for histopathology and immunohistochemistry, and for steroid analyses.

2.2. Histopathology

2.2.1. Immunohistochemistry of estrogen receptor alpha (ER α), estrogen receptor beta (ER β), and androgen receptor (AR)

For histopathology and immunohistochemistry, tissue samples were fixed in formalin, embedded in paraffin, and cut into 4 μ m sections. Mammary tumors were diagnosed on hematoxylin-eosin sections, following the WHO's classification system of canine mammary tumors [11].

Immunohistochemistry of ER α , ER β , and AR was performed on samples of 5 normal mammary glands, 32 selected malignant non-inflammatory mammary tumors (MMT), and on 14 IMC samples. Immunostaining was done on deparaffined sections, using the streptavidin-biotin-complex peroxidase method, after a high temperature antigen unmasking protocol (boiling slides in a pressure cooker for 2 min in buffer citrate, pH 6). The slides were cooled down in distilled water and washed in Tris-buffered-saline (TBS) (0.1 M Tris base, 0.9% NaCl, pH 7.4). Endogenous peroxidase activity was blocked in 1.5 ml H₂O₂/100 ml methanol for 15 min. ER α immunostaining was performed by overnight incubation at 4 °C with mouse monoclonal anti-human ER α (clone CC4-5, Novocastra, dilution 1:40). ER β and AR sections were incubated overnight at 4 °C with rabbit polyclonal antibodies (anti-ER β , Upstate Biotechnology, dilution 1:50; anti-AR Neomarkers, dilution 1:15). After the incubation with the mouse monoclonal primary antibodies (ER α), the slides were incubated with anti-mouse biotinylated secondary antibodies (Dako, dilution 1:200, 30 min at room temperature). ER β and AR slides were incubated with anti-rabbit biotinylated secondary antibodies (Vector Laboratories, 1:400, 30 min at room temperature). Afterwards, all the slides were incubated with streptavidin conjugated with peroxidase (Zymed, 1:400, 30 min at room temperature). All washes and dilutions were made in TBS. The slides were developed for 10 min with a chromogen solution containing 3,3'-diaminobenzidine tetrahydrochloride (Sigma Chemical Co.) and H₂O₂ in TBS. After washing in distilled water for 10 min, slides were counterstained

in hematoxylin (Sigma), washed in tap water, dehydrated, cleared in xylene, and mounted. Negative control slides were made by substituting the primary antibody with TBS. A normal canine uterus was used as a positive control for ER α and β . Adjacent normal mammary glands or hyperplasias were used as internal positive controls for ER α and β in many slides. A normal canine prostate was used as a positive control for AR. Normal canine sebaceous glands in the dermis were internal positive controls for AR immunostaining. Tumors were considered ER α , ER β , or AR positive when more than 10% of positive cells were observed in 10 representative selected fields. Counting was done with a computer-assisted image analyzer (Olympus MicroimageTM image analysis, software version 4.0 for Windows). Positive ER α , ER β , and AR immunostaining intensity was also evaluated simultaneously by two observers, scored in each case as low (+), moderate (++), or intense (+++), based on the most frequent intensity found in the stained nuclei.

2.2.2. Assessment of steroid concentrations in serum and tissue homogenate samples

2.2.2.1. *Preparation of tissue homogenates.* Samples for steroid analysis were maintained frozen until use. 0.5 g of mammary tissue were homogenized in 4 ml of PBS (pH 7.2) and centrifuged (3500 rpm, at 4 °C for 20 min). The supernatants were collected and aliquoted individually (–30 °C), until hormone assays.

2.2.3. Dehydroepiandrosterone, androstenedione, testosterone, estrone sulphate and 17 β -estradiol enzymeimmunoassay of serum and homogenate samples

DHEA, A4, T, SO4E1, and E2 levels of normal and neoplastic mammary tissue homogenates were assayed by competitive EIA previously validated in our laboratory. Homogenate samples were prepared by diluting 10 μ l of each homogenate in an assay buffer (1:2500 for dehydroepiandrosterone, androstenedione, testosterone, and estrone sulphate or 1:500 for 17 β -estradiol), and then extracted with 2 ml of diethyl ether (Sigma Co., St. Louis, MO, USA). Hundred microlitres of the supernatant were evaporated under a nitrogen stream (Turbovap, ZIMARK, Hopkinton, MA, USA).

Dehydroepiandrosterone, androstenedione, testosterone, and estrone sulphate concentrations in serum were expressed in ng/ml; tissue homogenate concentrations were expressed in ng/g. 17 β -Estradiol concentrations in serum were expressed in pg/ml, and tissue homogenate concentrations in pg/g.

2.3. Statistical analysis

The BMDP (Biomedical Data Program, Statistical Software Inc., Los Angeles, CA, USA) was used for statistical analysis. Differences between individual means were analyzed by the Pairwise t-test and the Bonferroni post-test to determine whether values were statistically different. All values were expressed as mean \pm S.E. Categorical variables were analyzed by Pearson and Yates χ^2 -tests. The grade of statistical concordance between AR/ER β positive/negative immunostaining was analyzed by the κ -test. In all statistical comparisons, $p < 0.05$ was accepted as denoting significant differences.

3. Results

3.1. Histopathology

Histopathology of the non-inflammatory malignant mammary tumors ($n = 42$) revealed several histologic subtypes: anaplastic ($n = 1$), solid ($n = 5$), and tubulopapillary carcinomas ($n = 28$); carcinomas in benign tumors ($n = 5$), carcinosarcomas ($n = 2$); an osteosarcoma ($n = 1$). Inflammatory mammary carcinomas were diagnosed as either solid and tubulopapillary carcinomas ($n = 12$) or as lipid rich carcinomas ($n = 2$). All cytologic vaginal smears revealed characteristics of anestrus.

3.2. ER α , ER β , and AR and immunohistochemistry

Results of ER α , ER β , and AR immunorexpression are detailed in Table 1.

3.3. Normal mammary glands

All samples of normal mammary glands were positive (++ to +++) with respect to ER α and ER β . ER α and ER β expression was low to moderate in cytoplasm (+ to ++), and moderate to intensely positive (++ to +++) in the nuclei of epithelial and myoepithelial cells in ducts and acini. The immunostaining was homogeneous in the samples, although the intensity of immunolabelling among the nuclei was variable. Some scattered stromal cells were positive. In general, the normal mammary glands showed low to moderate (+, ++) AR immunorexpression. AR expression was detected in the cytoplasm and nucleus of epithelial and myoepithelial cells, and in ducts and acini, with uniform distribution among the different mammary lobules. Stromal cells were positive or negative.

3.4. Non-IMC malignant tumors (MMT)

A marked heterogeneous distribution of ER α and AR immunostaining was found in positive malignant tumors. Most of the neoplasms were ER α negative (30/32, 93.70%), while 26/32 (81.25%) of MMT expressed ER β with different intensities (+ to +++)). An increase in intensity was observed in the AR immunostaining of this group of tumors compared to that of normal mammary glands. In general, all cellular neoplastic and stromal cellular types could express ER α , ER β , and AR. The positive/negative expression of AR/ER β was coincident in 68.75% of the cases (non-significant $p = 0.4$).

3.5. Inflammatory mammary carcinomas (IMC)

All IMC cases analyzed ($n = 14$) were negative with respect to ER α expression. ER β was expressed in all but one (13/14) of the cases analyzed. ER β was positive in all neoplastic cellular types as well as in infiltrating and metastatic (emboli) cells. AR was heterogeneously expressed and considered positive in 13/14 (92.86%) of the cases. The intensity of AR immunostaining (intense +++) was higher (non-significant $p = 0.1$) than in non-inflammatory malignant mammary tumors (Figs. 1 and 2). Highly malignant independent epithelial cells that invaded the dermis and neoplastic cells

Table 1 – Estrogen receptor α , estrogen receptor β , and androgen receptor immunohistochemistry

	Number of samples analyzed	Negative	Positive		
			Low (+)	Moderate (++)	Intense (+++)
Estrogen receptor α immunohistochemistry					
Normal mammary gland	5	0/5, 0.00%	0/5, 0.00%	2/5, 40.00%	3/5, 60.00%
Malignant non-IMC tumors	32	30/32, 93.70%	2/32, 6.30%	0/32, 0.00%	0/32, 0.00%
Inflammatory mammary carcinomas (IMC)	14	14/14, 100.00%	0/14, 0.00%	0/14, 0.00%	0/14, 0.00%
Total	51				
Estrogen receptor β immunohistochemistry					
Normal mammary gland	5	0/5 0.00%	0/5 0.00%	1/5 20.0%	4/5 80.0%
Malignant non-IMC tumors	32	6/32 18.75%	14/32 43.70%	9/32 28.12%	3/32 9.37%
Inflammatory mammary carcinomas (IMC)	14	1/14 7.14%	3/14 21.42%	6/14 42.85%	4/14 28.57%
Total	51				
Androgen receptor immunohistochemistry					
Normal mammary gland	5	0.00%	3/5 60.0%	2/5 40.0%	0.00%*
Malignant non-IMC tumors	32	5/32 15.62%	14/32 43.75%	8/32 25.00%	5/32 15.62%*
Inflammatory mammary carcinomas (IMC)	14	1/14 7.14%	4/14 28.57%	4/14 28.57%	5/14 35.71%*
Total	51				

* χ^2 -test: $p=0.1$.

in emboli showed an intense AR immunostaining. The positive/negative expression of AR/ER β was coincident in all 14 IMC cases studied ($p=0.000$).

3.6. Steroid concentrations in serum and tissue homogenate samples

The steroid hormone concentrations in serum and tissue homogenates are depicted in Tables 2 and 3. Hormone serum levels of dehydroepiandrosterone (DHEA), androstenedione (A4), testosterone (T), and estrone sulphate (SO4E1) were significantly higher ($p=0.001$, $p=0.02$, $p=0.001$, $p=0.001$) in IMC samples than in compared with malignant non-IMC tumor samples. 17 β -Estradiol concentrations were significantly lower in IMC samples ($p=0.01$), and similar to those obtained in normal mammary glands. Levels of all the steroids analyzed in tissue homogenates were two or three times higher in IMC samples than in malignant non-IMC tumor samples. Concentrations of SO4E1 were especially elevated in the IMC samples. There were significant positive correlations between tissue and serum values of DHEA ($r=0.76$, $p=0.001$), A4 ($r=0.74$,

$p=0.001$), T ($r=0.75$, $p=0.001$), and SO4E1 ($r=0.74$, $p=0.001$). E2 had a non-significant negative correlation ($r=-0.29$, $p=0.87$).

4. Discussion

To our knowledge, this is the first report relative to AR immunohistochemistry in canine mammary cancer and to estrogens or androgens in serum of dogs with benign or malignant mammary tumors, including inflammatory mammary carcinoma.

Inflammatory mammary carcinoma (IMC) is a distinct form of locally advanced mammary cancer in women [1,2,12] and bitches [3,5]. It is highly angiogenic and angioinvasive, with rapidly aggressive behaviour and metastatic potential [1-3,5,12]. In both species, it is considered to be the most malignant type of mammary cancer, with a fulminant clinical course and extremely poor survival rate [1-3,5,12]. In human IMC, the actual multimodality treatment, with or without surgery, has improved the disease-free survival and overall survival of patients [2,12]. Fortunately, it is a rare disease in both species, although its prevalence seems to have increased

Table 2 – Steroid hormone concentrations in serum samples

	Control dogs (n=10) (a)	a vs. b	Dogs with malignant tumor non-IMC (n=42) (b)	b vs. c	Dogs with inflammatory mammary carcinoma (IMC) (n=14) (c)	a vs. c
DHEA (ng/ml)	5.33 \pm 0.84 a	$p=0.004$	8.42 \pm 1.23 b	$p=0.001$	13.21 \pm 4.22 c	$p=0.001$
Androstenedione (ng/ml)	1.45 \pm 0.12 a	$p=0.03$	2.16 \pm 0.22 b	$p=0.02$	3.81 \pm 0.69 c	$p=0.01$
Testosterone (ng/ml)	6.92 \pm 0.73 a	$p=0.001$	16.46 \pm 1.30 b	$p=0.001$	35.43 \pm 2.27 c	$p=0.001$
Estrone sulphate (ng/ml)	1.22 \pm 0.13 a	$p=0.001$	2.90 \pm 0.23 b	$p=0.001$	6.24 \pm 0.40 c	$p=0.001$
17 β -Estradiol (pg/ml)	18.89 \pm 7.71 a	$p=0.001$	49.65 \pm 17.55 b	$p=0.01$	23.96 \pm 8.45 ac	$p=0.1$

Hormone values with different letters denoting statistical differences (a vs. b, a vs. c, and b vs. c).

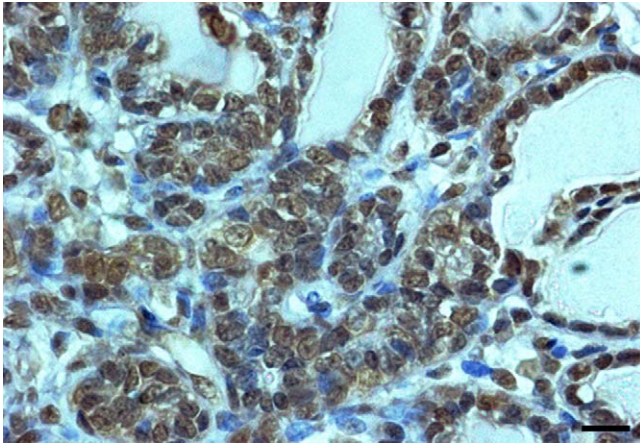


Fig. 1 – Canine mammary tumor. Tubular carcinoma (non-inflammatory mammary malignant tumor). Positive and negative nuclei of tumor cells. Low intensity of immunostaining in AR-positive nuclei. Streptavidin–biotin-peroxidase; bar = 22 μ m.

in the recent decades in the dog (from 4.4% to 7.6% of all mammary tumors [3]), and in women [6]. Some specific genetic alterations have been described that appear to cause the invasive “inflammatory” phenotype in human mammary epithelial cells [13]. Moreover, different endocrine mechanisms have been proposed to participate in canine IMC [5,7].

Sex steroid formation in peripheral tissues is well documented in humans [14]. Normal and neoplastic mammary glands are considered by some authors to be an endocrine tissue, particularly by virtue of their estrogen and androgen synthesis [15–22]. The action of estrogens and androgens (locally produced or not) is crucial in the neoplastic growth and progression of breast cancer, because of their interaction with specific receptors [23]. Interestingly, it has been demonstrated that estradiol increases vascular endothelial growth factor (VEGF), a key factor for angiogenesis [24]. Nevertheless, to our knowledge, there are no studies that refer to steroid

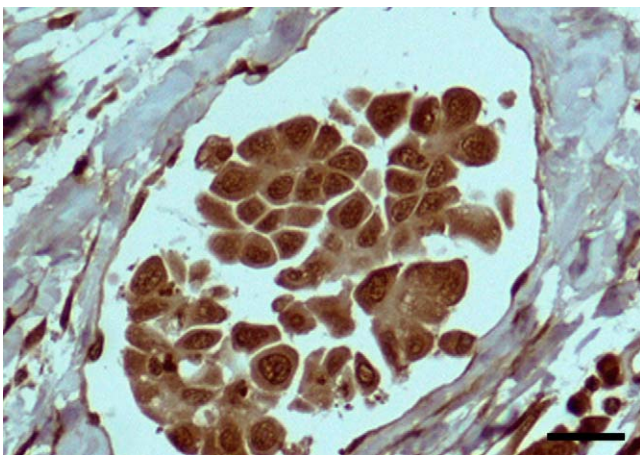


Fig. 2 – Canine mammary tumor. Inflammatory mammary carcinoma. All tumor cells (metastatic cells inside a lymphatic vessel) are intensely positive to AR. Streptavidin–biotin-peroxidase; bar = 44 μ m.

plasma levels in inflammatory breast cancer. There are several studies concerning serum concentrations of endogenous or exogenous sex hormones and the risk of breast cancer in general [25–28], and a few publications related to serum levels of steroids in women with benign or malignant mammary tumors [16,22,29,30]. In our preliminary study, a possible local synthesis of some steroid hormones in normal and neoplastic canine mammary glands was indicated [7]. To be rigorous, we should only compare our results here with serum hormonal levels of premenopausal breast cancer human patients in the luteal phase of their cycles, due to the anestrus situation of our cases.

In our canine samples (Table 3), 17β -estradiol concentration was significantly higher in malignant mammary tumors than in normal mammary glands. Concentrations of estradiol in canine IMC were also significantly higher than in other non-IMC malignant canine mammary tumors (MMT). Increased levels of estradiol in malignant mammary tissues were found in humans [19,31,32]. Similar increases of estrone sulphate and 17β -estradiol have been reported in the serum of premenopausal women with breast cancer (luteal phase) [29].

Estrone sulphate concentrations can represent an important reservoir for biologically active estrogens in mammary tumors [29,33–36]. Our study reveals high concentrations of estrone sulphate in canine mammary tissues and serum, increasing significantly in IMC cases (Tables 2 and 3). In human breast cancer, some authors have detected large amounts of estrone and estrone sulphate, although the results have been contradictory [19,29,31,32,34].

Normal and neoplastic human breast tissues also contain and produce several forms of androgens [21,22,31,37,38]. However, the information concerning intra-tissue and serum levels of androgens in women with breast cancer is sparse. In one study, no significant increases were indicated in malignant breast cancer cases versus cases of benign lesions, although a highly significant decrease of serum testosterone was found [29]. In the present study, tissue levels of DHEA, A4, and T were significantly elevated in IMC compared to MMT and to normal mammary glands (Table 3). A high proportion of the androgens found in the canine mammary tissues could be attributed to local synthesis.

The results of our study in dogs indicate higher concentrations of all the studied hormones in both non-inflammatory malignant mammary tumors and (especially) in inflammatory mammary carcinomas. Indeed, DHEA and $SO4E1$ levels in serum and in tissue homogenates were two or three times higher in IMC cases than in the other groups ($p < 0.001$). Moreover, we found a significant reduction of serum 17β -estradiol levels in dogs with MMT ($p < 0.01$), despite the high concentrations detected in corresponding tissue samples.

There are no direct studies about concentrations of steroid hormones in cases of human IMC. Recent studies have described a worse survival rate in post-menopausal obese IMC human patients [39]; it is known that adipose tissue is an important source of sex steroids in post-menopausal women [40]. The direct endocrine responsiveness of human IMC cells is only known by the presence of estrogen and progesterone receptors (ER and PR), in some cases. The majority of human IMC cases are ER and PR negative [12]. According to the literature, women with positive ER and PR IMC tumors have

Table 3 – Steroid hormone concentrations in tissue homogenates

	Normal mammary tissue (n = 10) (a)	a vs. b	Malignant tumor non-IMC (n = 42) (b)	b vs. c	Inflammatory mammary carcinoma (IMC) (n = 14) (c)	a vs. c
DHEA (ng/ml)	69.72 ± 5.28 a	p = 0.001	252.67 ± 10.86 b	p = 0.001	715.25 ± 82.42 c	p = 0.001
Androstenedione (ng/ml)	32.62 ± 5.65 a	p = 0.001	64.73 ± 9.49 b	p = 0.001	698.54 ± 59.42 c	p = 0.001
Testosterone (ng/ml)	40.28 ± 0.97 a	p = 0.001	13.09 ± 4.45 b	p = 0.001	287.43 ± 6.89 c	p = 0.001
Estrone Sulphate (ng/ml)	398.74 ± 9.64 a	p = 0.001	534.98 ± 41.23 b	p = 0.001	3123.08 ± 412.56 c	p = 0.001
17β-Estradiol (pg/ml)	133.29 ± 14.71 a	p = 0.001	224.32 ± 18.43 b	p = 0.001	723.75 ± 38.12 c	p = 0.001

Hormone values with different letters denoting statistical differences (a vs. b, a vs. c, and b vs. c).

a better prognosis than women with negative IMC tumors [6,41].

Steroid receptors in canine mammary tumors are still under study. Most of the studies are focused on ER α [8] and progesterone receptor immunohistochemical detection [9]. Contrary to normal human mammary gland, normal canine epithelial mammary gland are positive to ER α . ER α positive canine mammary tumors and PR positive IMC tumors generally have better clinical outcomes [5,8]. Recently, the expression of ER β has been described [10] in canine malignant mammary tumors. To our knowledge, there are no previous studies of AR immunohistochemistry in canine mammary tissues.

The expression and role of ER β in human breast cancer is controversial, with either decreased or equal expression reported in normal and benign mammary tissues according to different studies [42]. In canine IMC cases, significantly reduced levels of serum E2 ($p = 0.01$), together with the high amounts found in IMC homogenates, suggests a local utilization of this hormone, probably via ER β , since all canine IMC cases were ER α negative. This fact could explain the non-significant negative correlation found between serum and tissue levels of E2.

Literature regarding AR expression in human breast cancer varies with the study and the method of detection employed. Immunohistochemistry, RT-PCR, and Western blot studies of AR in human breast cancer cases offer contradictory results on its percentage of expression, relation with histological type, malignancy, prognosis, and correlation with other steroid receptors [19,21,42,43]. Lately, a consistent study using AR immunohistochemistry demonstrates that androgen receptors are commonly expressed in non-invasive and invasive human breast carcinomas, being the highly malignant carcinomas ER-negative and PR-negative, but AR-positive [44]. In the canine IMC tumors studied here, we found strong immunorexpression of AR, even in highly malignant infiltrating or metastatic cells (non-significant, probably due to low number of cases) (Figs. 1 and 2). In a previous study on canine IMC, a high percentage of PR positive cases (71.4%) was also indicated [5]. A correlation between AR and PR, and the absence of correlation with ER, has been reported in human breast mammary tumors [13,19]. Immunohistochemical examination of AR in cases of human IMC would provide additional information about steroid receptors to potentially lead the way to new therapeutic strategies. Future studies about the production and metabolism of steroid hormones in human inflammatory breast cancer would be desirable to know the role of these hormones and to give expectations to the develop-

ment of new therapies directed to block determined steroid pathways.

5. Conclusions

Androgens and estrogens levels were significantly increased in canine IMC homogenates and serum (except estradiol serum levels that were reduced). AR and ER β were intensely expressed as shown by immunohistochemistry in IMC cases. Future studies about the production and metabolism of steroid hormones in human inflammatory breast cancer would be desirable to know the precise role of these hormones and to give expectations to the development of new therapies directed to block determined steroid pathways.

Acknowledgment

This study has been supported by the Spanish Government National Research Project SAF2005-03559.

REFERENCES

- [1] Giordano SH. Update on locally advanced breast cancer. *Oncologist* 2003;8:521–30.
- [2] Tavassoli FA. Inflammatory carcinoma. Infiltrating carcinomas: special types. In: *Pathology of the breast*. 2nd ed. New York: Mc Graw-Hill; 1999. p. 538–41.
- [3] Perez-Alenza MD, Tabanera E, Peña L. Inflammatory mammary carcinoma in dogs: 33 cases (1995–1999). *J Am Vet Med Assoc* 2001;219:1110–4.
- [4] Perez-Alenza MD, Jiménez MA, Nieto A, Peña L. First description of feline inflammatory mammary carcinoma: clinicopathological and immunohistochemical characteristics of three cases. *Breast Cancer Res* 2004;6:300–7.
- [5] Peña L, Perez-Alenza MD, Rodriguez-Bertos A, Nieto A. Canine inflammatory mammary carcinoma. Histopathology, immunohistochemistry and clinical implications of 21 cases. *Breast Cancer Res Treat* 2003;78:141–8.
- [6] Brooks HL, Mandava N, Pizzi WF, Shah S. Inflammatory breast carcinoma: a community hospital experience. *J Am Coll Surg* 1998;186:622–9.
- [7] Peña L, Silvan G, Perez-Alenza MD, Nieto A, Illera JC. Steroid hormone profile of canine inflammatory mammary carcinoma: a preliminary study. *J Steroid Biochem Mol Biol* 2003;84:211–6.
- [8] Nieto A, Peña L, Perez-Alenza MD, Sanchez MA, Flores JM, Castaño M. Immunohistologic detection of estrogen

- receptor alpha in canine mammary tumors: clinical and pathologic associations and prognostic significance. *Vet Pathol* 2000;37:239–47.
- [9] Lantinga IS, van Leeuwen E, van Garderen JA, Rutteman GR. Cloning and cellular localization of the canine progesterone receptor: co-localization with growth hormone in the mammary gland. *J Steroid Biochem Mol Biol* 2000;75:219–28.
- [10] Martín de las Mulas J, Ordás J, Millán MY, Chacón F, De Lara M, Espinosa de los Monteros A, Reymundo C, Jover A. Immunohistochemical expression of estrogen receptor β in normal and tumoral canine mammary glands. *Vet Pathol* 2004;41:269–72.
- [11] Misdorp W, Else RW, Hellmén E, Lipscomb TP. Histological classification of mammary tumors of the dog and cat. Second series, vol. 7. Washington: Armed Forces Institute of Pathology and World Health Organization; 1999.
- [12] Kleer CG, van Golen KL, Zhang Y, Wu ZF, Rubin MA, Merajver SD. Characterization of RhoC expression in benign and malignant breast disease: a potential new marker for small breast carcinomas with metastatic ability. *Am J Pathol* 2002;160:579–84.
- [13] Van Golen KL, Wu ZF, Qiao XT, Bao LW, Merajver SD. RhoC GTPase, a novel transforming oncogene for human mammary epithelial cells that partially recapitulates the inflammatory breast cancer phenotype. *Cancer Res* 2000;60:5832–8.
- [14] Labrie F, Luu-The V, Labrie C, Simard J. DHEA and its transformation into androgens and estrogens in peripheral target tissues: intracrinology. *Front Neuroendocrinol* 2001;22:185–212.
- [15] Blankenstein MA, Van de Ven J, Maitimu-Smeele I, Donker GH, Chr de Jong P, Daroszewski J, Szymczak J, Milewicz A, Thijssen JHH. Intratumoral levels of estrogens in breast cancer. *J Steroid Biochem Mol Biol* 1999;69:293–7.
- [16] Vermeulen A, Delyspere JP, Paridaens R. Steroid dynamics in the normal and carcinomatous mammary gland. *J Steroid Biochem* 1986;25:799–802.
- [17] Killinger DW, Perel E, Daniilescu D, Kharlip L, Blackstein ME. Aromatase activity in the breast and other peripheral tissues and its therapeutic regulation. *Steroids* 1987;50:523–36.
- [18] Maggolini M, Carpino A, Bonfiglio D, Pezzi V, Rago V, Marisco S, Picard D, Andò S. The direct proliferative stimulus of dehydroepiandrosterone on MCF7 breast cancer cells is potentiated by overexpression of aromatase. *Mol Cell Endocrinol* 2001;184:163–71.
- [19] Thijssen JHH, Blankenstein MA, Miller WR, Milewicz A. Estrogens in tissues: uptake from the peripheral circulation or local production. *Steroids* 1987;50:1–3.
- [20] Thijssen JHH, Blankenstein MA, Donker GH, Daroszewski J. Endogenous steroid hormones and local aromatase activity in the breast. *J Steroid Biochem Mol Biol* 1991;39:799–804.
- [21] Blankenstein MA, Maitimu-Smeele I, Donker GH, Daroszewski J, Milewicz A, Thijssen JHH. Tissue androgens and the endocrine autonomy of breast cancer. *J Steroid Biochem Mol Biol* 1992;43:167–71.
- [22] Liao DJ, Dickson RB. Roles of androgens in the development, growth, and carcinogenesis of the mammary gland. *J Steroid Biochem Mol Biol* 2002;80:175–89.
- [23] Dimitrakakis C, Konstadoulakis M, Messaris E, Kymionis G, Karayannis M, Panoussopoulos D, Michalas S, Androulakis G. Molecular markers in breast cancer: can we use c-erbB-2, p53, bcl-2 and bax gene expression as prognostic factors? *Breast* 2002;11:279–85.
- [24] Dabrosin C, Margetts PJ, Gauldie J. Estradiol increases extracellular levels of vascular endothelial growth factor in vivo in murine mammary cancer. *Int J Cancer* 2003;107:535–40.
- [25] Cauley JA, Lucas FL, Kuller LH, Stone K, Browner W, Cummings SR. Elevated serum estradiol and testosterone concentrations are associated with a high risk for breast cancer. *Ann Intern Med* 1999;130:270–7.
- [26] Grace PB, Taylor JI, Low YL, Luben RN, Mulligan AA, Botting NP, Dowsett M, Welch AA, Khaw KT, Wareham NJ, Day NE, Bingham SA. Phytoestrogen concentrations in serum and spot urine as biomarkers for dietary phytoestrogen intake and their relation to breast cancer risk in European prospective investigation of cancer and nutrition-norfolk. *Cancer Epidemiol Biomarkers Prev* 2004;13:698–708.
- [27] Sturgeon SR, Potischman N, Malone KE, Dorgan JF, Daling J, Schairer C, Brinton LA. Serum levels of sex hormones and breast cancer risk in premenopausal women: a case-control study (USA). *Cancer Cause Control* 2004;15:45–53.
- [28] Key TJ, Appleby PN, Reeves GK. Hormones breast cancer collaborative group. Body mass index, serum sex hormones, and breast cancer risk in postmenopausal women. *J Natl Cancer Inst* 2003;95:1218–26.
- [29] Mady EA, Ramadan EEDH, Ossman AA. Sex steroid hormones in serum and tissue of benign and malignant breast tumors patients. *Dis Mar* 2000;16:151–7.
- [30] Asseryanis E, Ruecklinger E, Hellan M, Kubista E, Singer CF. Breast cancer size in postmenopausal women is correlated with body mass index and androgen serum levels. *Gynecol Endocrinol* 2004;18:29–36.
- [31] Perel E, Davis S, Killinger DW. Androgen metabolism in male and female breast tissue. *Steroids* 1981;37:345–52.
- [32] Chetrite GS, Cortes-Prieto J, Philippe JC, Wright F, Pasqualini JR. Comparison of estrogen concentrations, estrone sulfatase and aromatase activities in normal, and in cancerous, human breast tissues. *J Steroid Biochem Mol Biol* 2000;72:23–7.
- [33] Santen RJ, Leszczynski D, Tilson-Mallet N, Feil PD, Wright C, Manni A. Enzymatic control of estrogen production in human breast cancer: relative significance of aromatase versus sulfatase pathways. *Ann NY Acad Sci* 1986;464:126–37.
- [34] Pasqualini JR, Gelly C, Nguyen BL, Vella C. Importance of estrogen sulfates in breast cancer. *J Steroid Biochem* 1989;34:155–63.
- [35] Pasqualini JR, Chetrite G, Blacker C, Feinstein MC, Delalonde L, Talbi M, Maloche C. Concentrations of estrone, estradiol, and estrone sulphate and evaluation of sulfatase and aromatase activities in pre- and post-menopausal breast cancer patients. *J Clin Endocrinol Metab* 1996;81:1460–4.
- [36] Billich A, Nussbaumer P, Lehr P. Stimulation of MCF-7 breast cancer cell proliferation by estrone sulphate and dehydroepiandrosterone sulphate: inhibition by novel non-steroid sulfatase inhibitors. *J Steroid Biochem Mol Biol* 2000;73:225–35.
- [37] Perel E, Killinger DW. The metabolism of androstenedione and testosterone to C19 metabolites in normal breast, breast carcinoma and benign prostatic hypertrophy tissue. *J Steroid Biochem* 1983;29:1135–9.
- [38] Brignardello E, Cassoni P, Migliardi M, Pizzini A, Di Monaco M, Boccuzzi G, Massobrio M. Dehydroepiandrosterone concentration in breast cancer tissue is related to its plasma gradient across the mammary gland. *Breast Cancer Res Treat* 1995;33:171–7.
- [39] Chang S, Alderfer JR, Asmar L, Buzdar AU. Inflammatory breast cancer survival: the role of obesity and menopausal status at diagnosis. *Breast Cancer Res Treat* 2000;64:157–63.

- [40] Szymczak J, Milewicz A, Thijssen JHH, Blankenstein MA, Daroszewski J. Concentration of sex steroids in adipose tissue after menopause. *Steroids* 1998;63:319-21.
- [41] Wilke D, Colwell B, Dewar R. Inflammatory breast carcinoma: comparison of survival of those diagnosed clinically, pathologically, or with both features. *Am Surg* 1998;64:428-31.
- [42] Conde I, Alfaro JM, Fraile B, Ruiz A, Paniagua R, Arenas MI. DAX-1 expression in human breast cancer: comparison with estrogen receptors ER-alpha, ER-beta and androgen receptor status. *Breast Cancer Res* 2004;6:140-8.
- [43] Selim AG, El-Ayat G, Wells CA. Androgen receptor expression in ductal carcinoma in situ of the breast: relation to oestrogen and progesterone receptors. *J Clin Pathol* 2002;55:14-6.
- [44] Moinfar F, Okcu M, Tsybrovskyy O, Regitnig P, Lax SF, Weybora W, Ratschek M, Tavassoli FA, Denk H. Androgen receptors frequently are expressed in breast carcinomas: potential relevance to new therapeutic strategies. *Cancer* 2003;98:703-11.